

Attachment Challenges in Compromised Situations

Functionality and esthetically pleasing results driven by dental team communication.

By Dennis Urban, CDT

Whether it is an implant overdenture or an attachment overdenture using existing natural dentition, the dental team eventually encounters cases that challenge both the dentist and the dental technician. One such case recently came to the attention of the author, a technician, who received several study casts from John Merrill DDS, director of the Carolinas Center for Oral Health. Dr. Merrill asked for an opinion about the patient's existing oral situation and set up a meeting at which to review the case scenario at his office.

Based on photographs and the study models, the case seemed odd; in addition to having malocclusion, it appeared that the patient had some type of deformity on the palate and alveolar ridge. The patient was also wearing an orthodontic wire-retained prosthesis with some anterior denture teeth attached to it (Figure 1 and Figure 2). From the meeting with Dr. Merrill and his associates at their office, it was apparent

that this was a very special case, and the dental team members wanted to do all they could for this young patient, who had many challenges ahead of him. The doctors informed the author that the patient was referred for orthognathic surgery and already had multiple repairs. In fact, the patient had eight surgeries, including primary repair, alveolar grafts, and iliac grafts.

This definitely was a challenging case and the patient clearly required treatment—both short- and long-term. The dental team decided that, for the short term, they would make an appliance entirely out of acetal resin. They made a duracetal framework with overlays on the posterior teeth with denture teeth set on the anterior region, and then injected the entire case out of acetal resin. Then he removed the actual denture teeth during the boil-out process and replaced them with the injected acetal resin material.

The author also applied tissue-shaded composite over the acetal resin for a more natural effect. While the esthetics on the case were compromised by

the monochromatic effect of the acetal resin, this was a dramatic improvement over the replaced prosthesis.

This type of prosthesis would be both kind to natural dentition and also prove to be functional. However, long-term retention was a concern. The photograph in Figure 3 shows the appliance after 6 months of wear. The appliance functioned well—in fact, better than was expected—but to devise a long-term solution, the team needed a type of attachment for an overdenture type case scenario. As implants were out of the question, the dental team created a low-profile attachment in which the doctor would use natural dentition with a post and core. Their solution and correct choice was Rhein83's low-profile OT Equator attachments.

The Rhein83 OT Equator is a 3-in-1 system. This system offers multiple solutions for treatment planning when stability and space limitations are a consideration. The OT Equator has the lowest profile and smallest diameter available, as well as a vertical height of a 2.1-mm and a diameter of

4.4 mm. It is compatible with all implant brands with cuff heights from 0.5 mm to 7 mm and includes multiple levels of retentive caps, which are retained by steel housings.

It is available in three versions: implant abutment, prefabricated titanium threaded for all CAD/CAM, or cast bar connections with a standard 2-mm thread and castable. For this particular case, the castable equator was chosen.

First the sites for the post and core copings were prepared (Figure 4), and an impression was sent to the laboratory (Figure 5). After the model work was finished (Figure 6), the technician waxed up the copings with castable equator patterns attached to the copings (Figure 7). The copings were cast and finished (Figure 8). At this point, both the impression copings and the Equator metal housing with inserts were ready to be sent to Dr. Merrill (Figure 9).

Next, the post and core copings were cemented, the impression coping was placed, and an impression was taken (Figure 10 through Figure 12). The impression was then loaded with Equator analogs and poured (Figure 13). The final models were mounted on an Artex articulator using a face-bow (Figure 14). This ensured that the prosthesis would be made exactly to the patient's cranium/axis relationship.

Dr. Merrill wanted to convert the original temporary appliance to a Rhein83 Equator-retained partial to be used as a spare and also to be worn while a new, more esthetic partial was being made. To do this, the doctor picked up the Equator housings and inserts in a reline impression. The team then

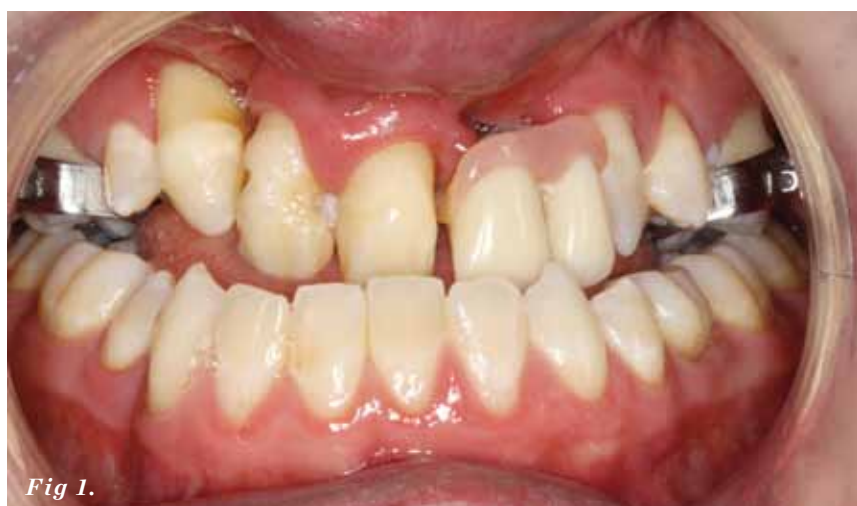

Fig 1.



Fig 2.

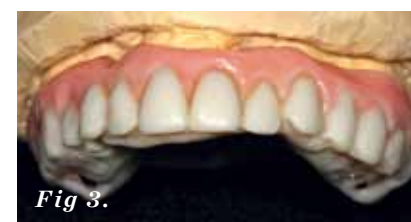

Fig 3.

Fig 1. An orthodontic wire-retained prosthesis.

Fig 2. A saggital view of the patient.

Fig 3. An acetal resin appliance after 6 months of wear.

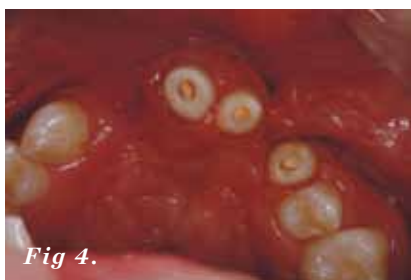

Fig 4.

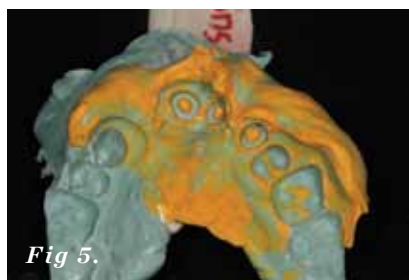

Fig 5.

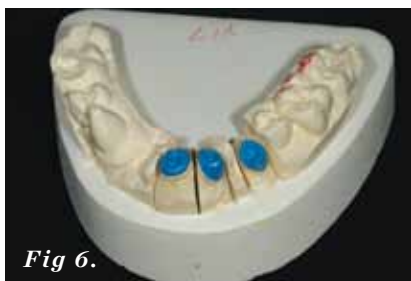


Fig 6.



Fig 7.



Fig 8.



Fig 9.

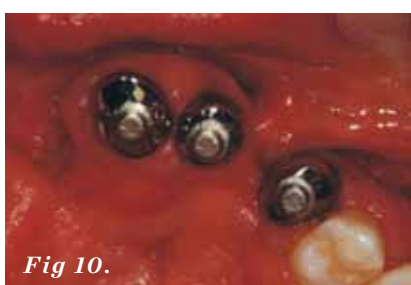

Fig 10.

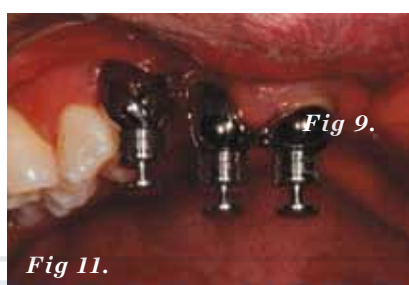

Fig 11.

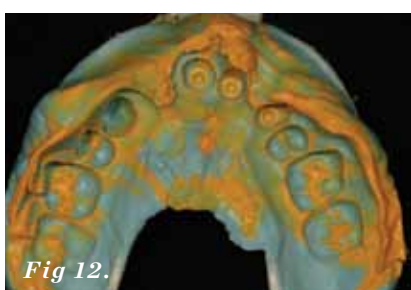


Fig 12.



Fig 13.

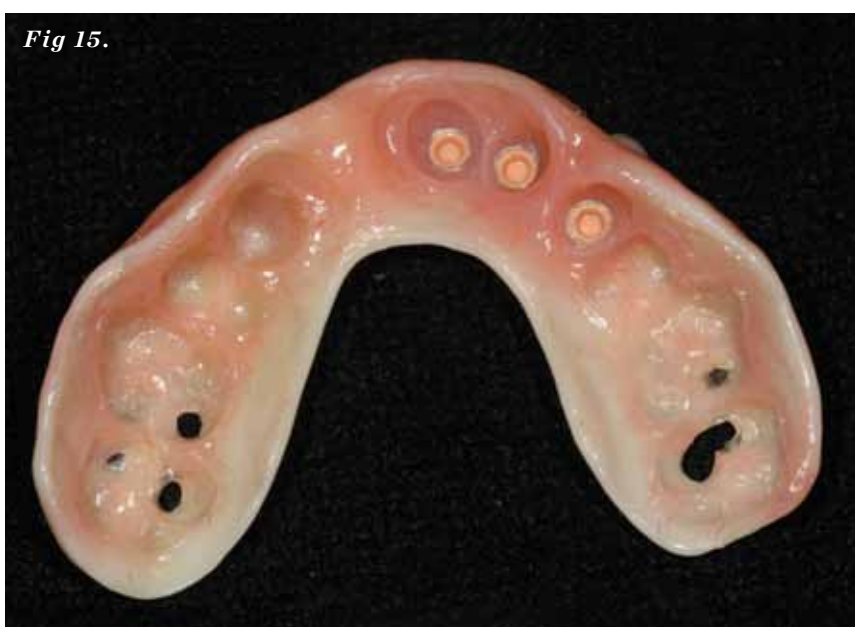

Fig 15.

Fig 4. The post and core sites were prepared.

Fig 5. Impression of the prepared sites.

Fig 6. The finished model work.

Fig 7. Waxed up copings with Equator patterns.

Fig 8. Finished and polished copings.

Fig 9. Post, core, and impression copings.

Fig 10. The Equator copings were cemented in place.

Fig 11. The Equator impression copings were ready to be picked up in the impression.

Fig 12. The final impression with impression copings.

Fig 13. The impression was loaded with Equator analogs.

Fig 14. The models were mounted using the face-bow transfer.

Fig 15. Acetal resin appliance with Equator housings was picked up in reline impression.

Fig 16. The waxed denture was prepared for the patient and doctor's approval

relined the appliance and processed the Equator attachments at the laboratory. (Figure 15).

The dental team is in the process of making a much more esthetic final restoration. Part 2 of this article will show photographs of the outcome. The final restoration will be a combination of an acetal resin framework with overlays on some of the posterior teeth to compensate for the malocclusion, and Ivoclar Vivadent denture teeth will be used to create more natural-looking esthetics. Figure 16 shows the waxed-up appliance (Figure 16).

The Rhein83 Equator attachments proved to be the right solution for a compromised situation. The success in the planning and execution of this particular case is due in part to the excellent communication of the dentists and dental technicians. The combination of communication, technical expertise, and the right materials culminated in the achievement of the ultimate goal—patient satisfaction and function.

Dennis Urban, CDT, has worked in dental technology for 35 years and was the recipient of the 2007 NADL Excellence in Education award. He is currently the technical consultant and removable manager for Drake Precision Dental Laboratory in Charlotte, North Carolina.

FOR MORE INFORMATION, CONTACT:

Rhein83 USA, Inc.

Phone: 877-778-8383

Web: www.rhein83usa.com

E-mail: info@rhein83usa.com

Disclaimer

The preceding material was provided by the manufacturer. The statements and opinions contained therein are solely those of the manufacturer and not of the editors, publisher, or the Editorial Board of *Inside Dental Technology*.

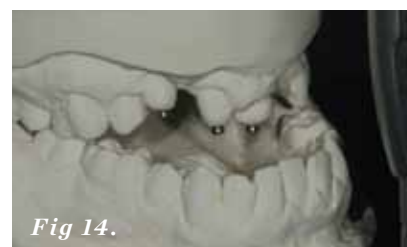

Fig 14.

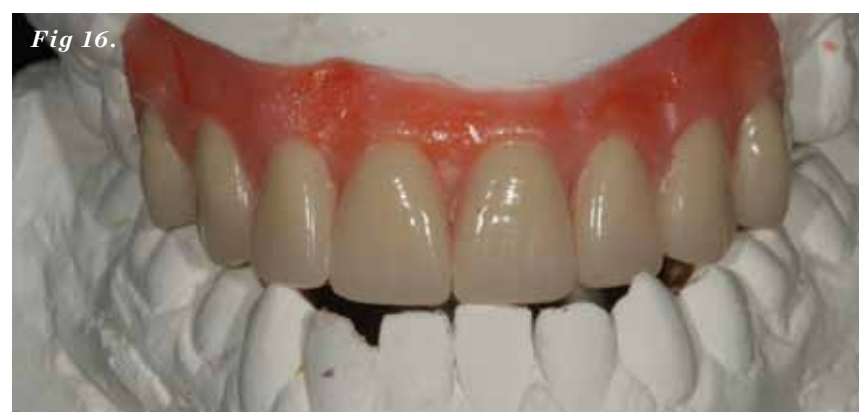

Fig 16.