

Rehabilitation of the edentulous maxilla – digital approach

Authors: Dr Francesco Benvenuto & Giorgio Poma, Italy

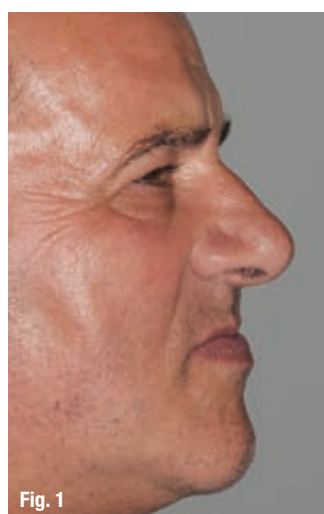

Fig. 1

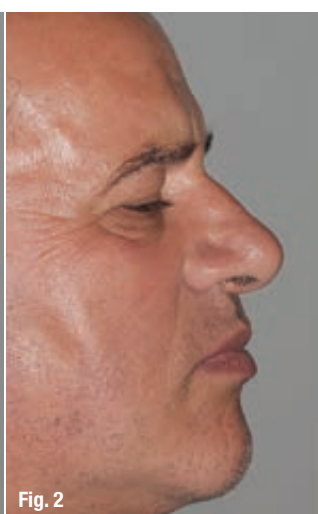

Fig. 2

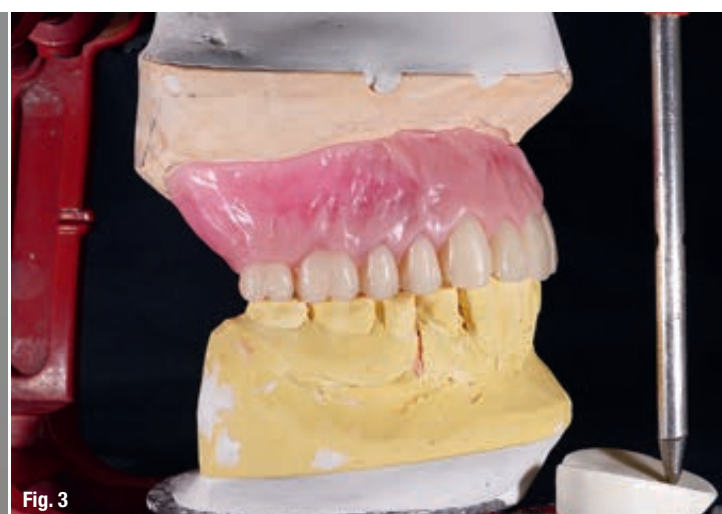

Fig. 3

Initial situation

A 57-year-old male presented with a partial upper removable prosthesis, with mucous support held by cast clasps on teeth 17 and 18, which were parodon-

topathic. Part of tooth 27 still remained, which would be extracted; in the lower arch was a removable frame denture with cast clasps (Figs. 1–3). The patient had a very pronounced third class occlusal relationship. The patient's request was to be able to chew properly with a stable prosthesis that could partially harmonise the volume of the perioral tissues.

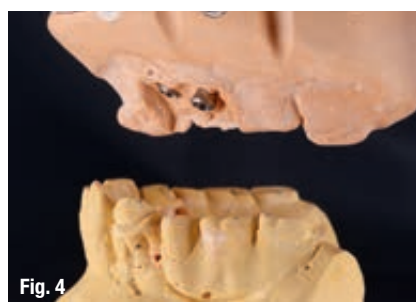

Fig. 4

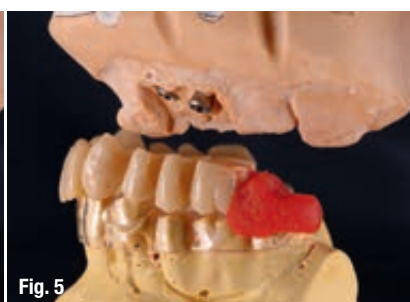

Fig. 5

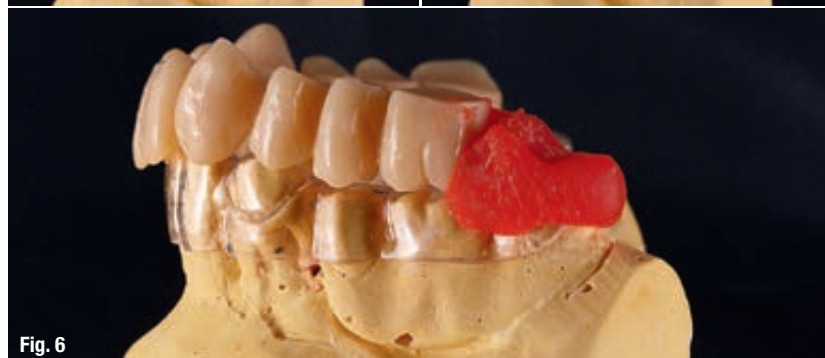

Fig. 6

In the first clinic session, alginate impressions were taken and chewing patterns were studied to produce study models on which to develop the diagnostic wax-up.

The analysis of the models showed a considerable overjet discrepancy between the two arches; the upper one showed an irregular bone crest with paraffinic keratoses caused by the existing prosthesis.

The diagnostic wax-up was then produced without considering the crests of the patient, but instead placing the dentition according to the first class occlusal relationship. This increased the vestibular flange volumes to give correct mucous support in order to restore a pleasing profile of the patient's lip.

After the aesthetic and functional tests, the patient approved the design of a total prosthesis supported

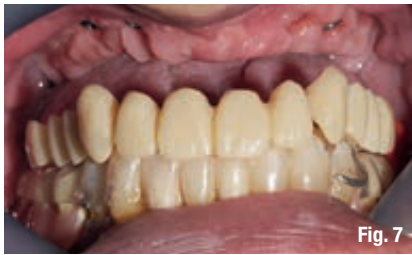

Fig. 7

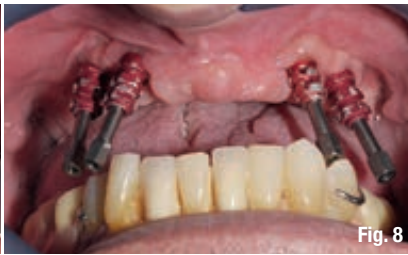

Fig. 8

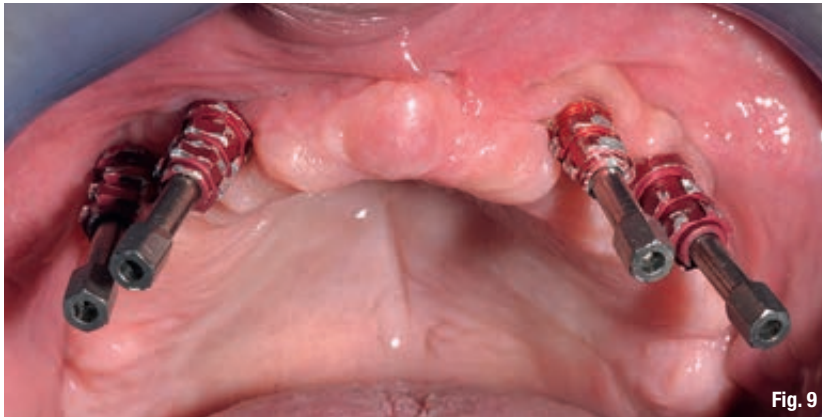


Fig. 9

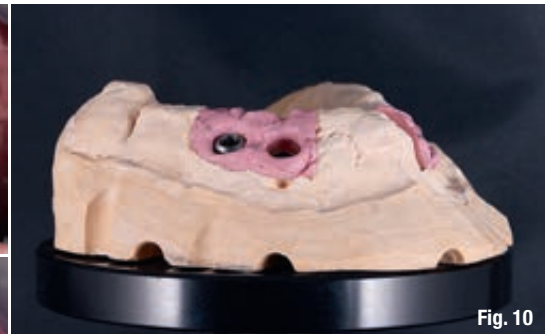

Fig. 10



Fig. 11

by four bar-connected implants located in the canine areas of the maxilla.

In agreement with the surgeon, it was decided to use the diagnostic wax-up to make a surgical template that would allow the surgeon to place the implants in areas with a more favourable bone density, which also indicated exactly the axis of insertion of the prosthesis and of the primary bar.

The diagnostic wax-up was then duplicated using a 1.5 mm thick thermos disk in which the acrylic resin was cast, thus obtaining an upper flange and a palate-free flange; a second template was then produced on the lower model on which the resin diagnostics was fixed, thus obtaining a three-dimensional vision of the volumes and the sagittal assembly inclination (Figs. 4–6).

These templates allowed the surgeon to work freely on the patient's tissues and to maintain the control of the insertion axis of the future prosthesis that the patient initially approved.

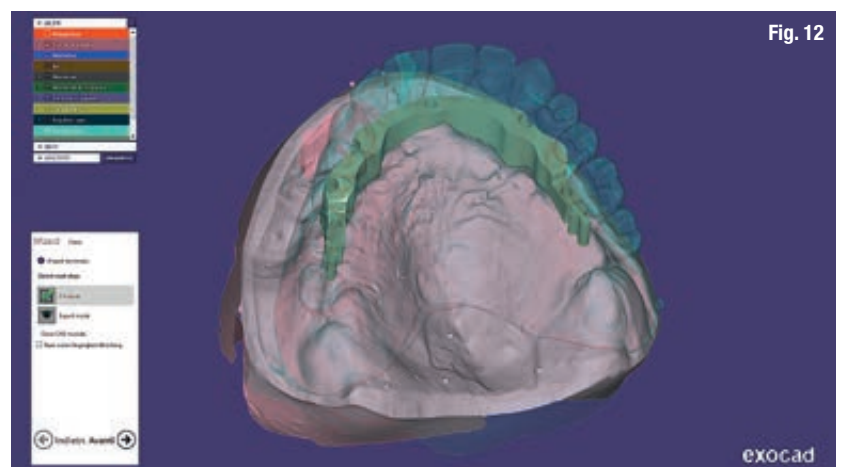


Fig. 12

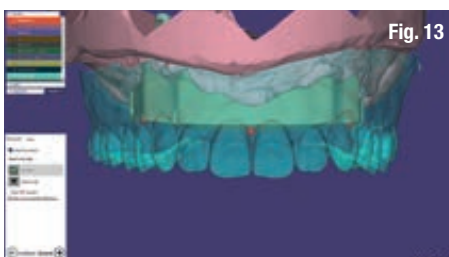


Fig. 13

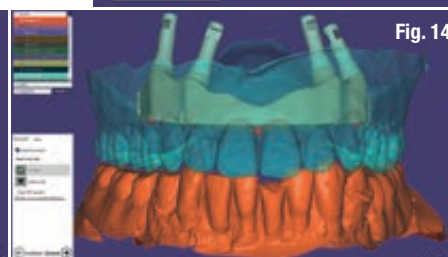


Fig. 14

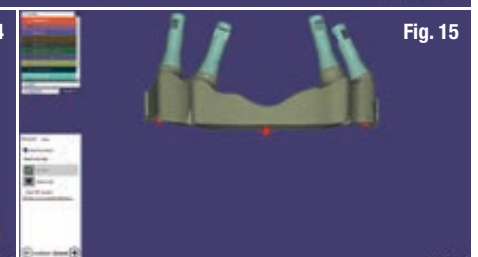

Fig. 15

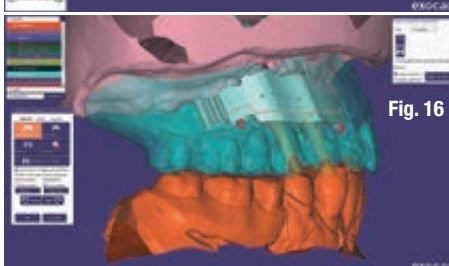


Fig. 16

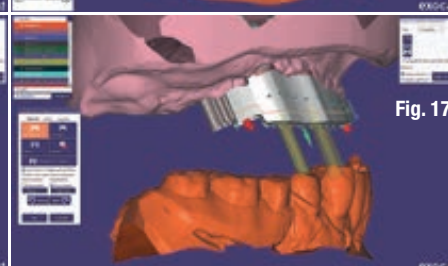


Fig. 17

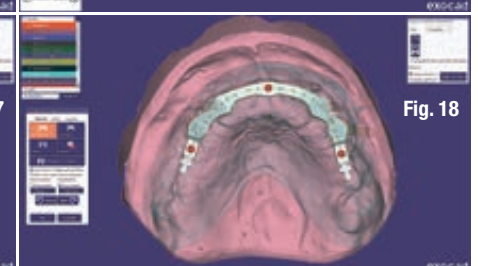
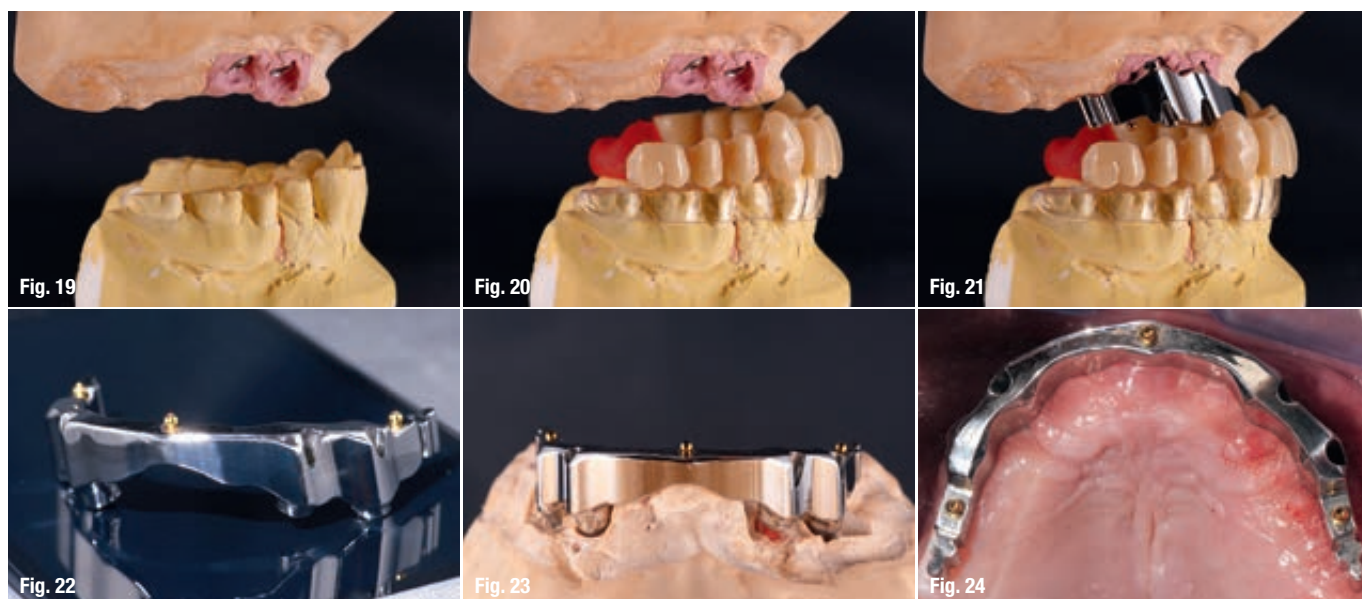


Fig. 18



Surgery

The medical and dental history did not highlight local pathologies that would contraindicate the use of osteointegrated implants for prosthetic support. The third skeletal class favoured the insertion of the implant fixture with vestibular inclination in line with the major axis of the residual crest. The guiding template, prepared in the laboratory, was positioned on the lower arch to have an intraoperative reference of the correct implant axis, and four 3.3 mm diameter x 10 mm Straumann Standard Plus implants were inserted, a regenerative with heterologous bone (Botiss cerabone) in the 22, 14 vestibular dehiscence area and in the alveoli of the 23. The bone consistency of D3, however, provided a primary stability of 35 N*cm

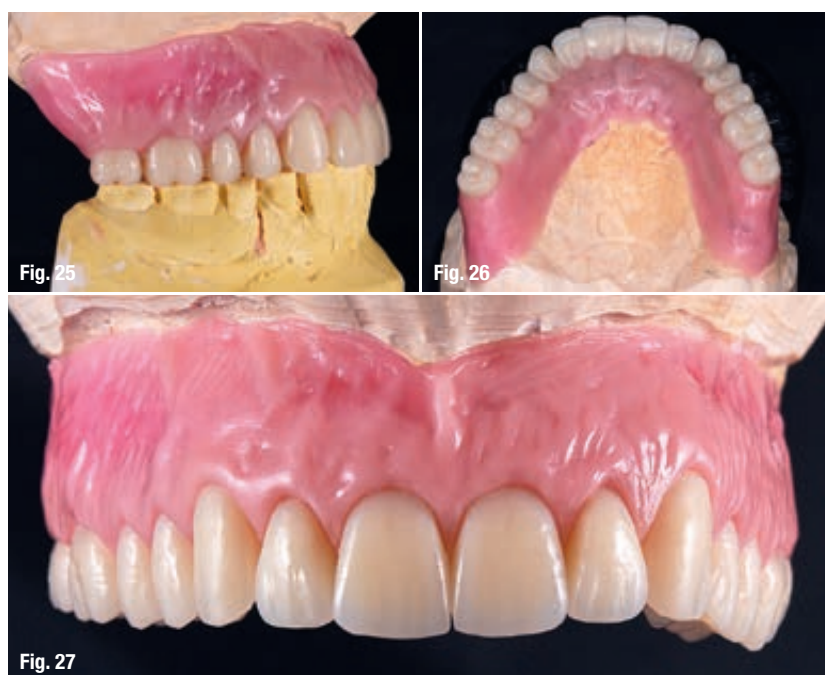measured with a dynamometer key. After 12 weeks, the implants were revealed, the keratinised tissues were repositioned around the healing screws and the first impression in alginate was taken. Once the models were developed, the individual fenestrated impression trays for the implant transfers were produced and then the definitive impression was taken (Figs. 7–9).

Prosthetic part

The position impression was developed with a pink silicone and in extra-hard Fuji Rock optiscan type 4 plaster to simulate the gingiva around the analogues (Figs. 10 & 11).

The wax rims with light-curing resin bases were produced in order to simulate the needed volumes for the labial support; its dimensions were of 22 mm height in the front and 20 mm in the back, with a thickness of 2 mm in the front and 4/6 mm in the back. Once tested and adapted the base with the Candulor occlusal fork aligning the upper wax in parallel with the bipupillary line, and laterally in parallel to the Camper plane which proceeds from the lower margin of the trago to the front nasal spine. The labial vestibulum volume was adapted to the aesthetic needs. Using the form selector, the shape of the anterior teeth was determined as corresponding to the form B63 Sr Phonares 2 Ivoclar, while the posterior teeth were determined as the A2 Bonartic Candulor A2.

The values recorded on the Stratos Ivoclar articulator were transferred through the slider of the horizontal plane by first mounting the upper and consequently the lower antagonist model. The teeth were assembled, which was then tested in the oral cavity for the patient by performing phonetic tests and extraoral evaluations.



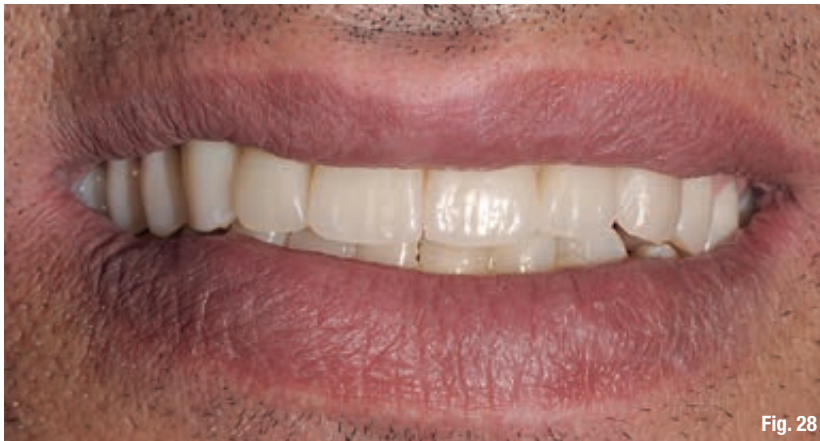

Fig. 28

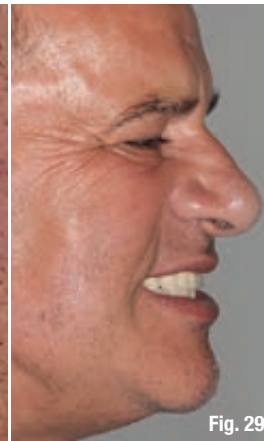

Fig. 29

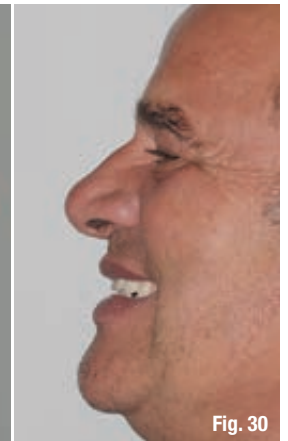

Fig. 30

Design and milling bar

The set-up, the upper model and lower model were scanned in order to design a 2°Cad bar, using the silicone keys indicating the volumes obtained from the teeth set-up for the correction of the third class as a reference. In this case, the vestibularisation of the bar was much more accentuated to follow the tilt pattern of the teeth set-up. In the design, three Rhein 83 threaded Micro Spheres and vertical frictional attachments distally were inserted. The 'STL' file of the bar with the corresponding 'construction info' file was inserted in the CAM with the set-up of the specific strategies for the connections and the attachments

present. The bar was milled from a chrome-cobalt disk using the 5-axis dental miller Orotig Whitec 5.2.

At the end of the milling cycle, the bar was detached from the milled wafer, the Sheffield test was performed, placing the bar on the model by pointing only one screw to the right and then to the left to verify the precision of the connections on the implants. The same test was performed in the oral cavity, with additional fit tests using control Rx. The threaded sleeves were cemented with composite material in the appropriate milled holes in the bar. As a result, the Rhein 83 threaded Micro Spheres attachments were screwed in. The counter bar was modelled with the castable



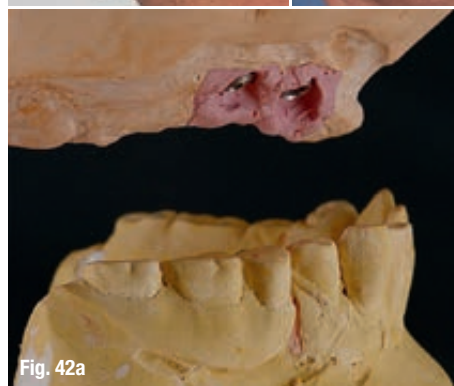
Fig. 31



Fig. 32

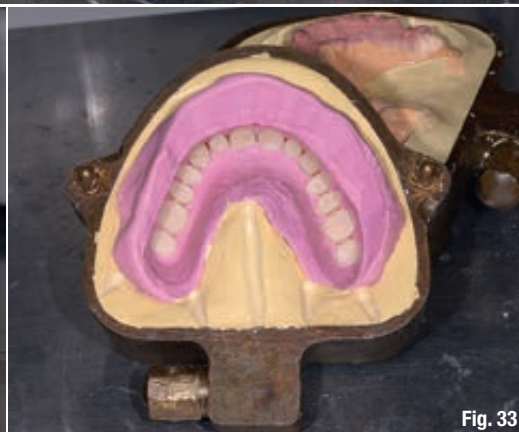
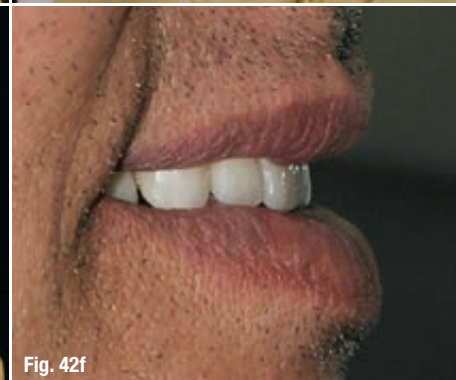
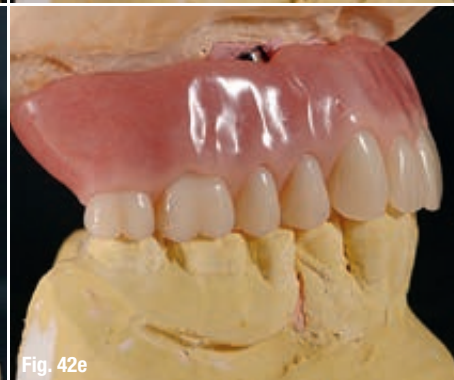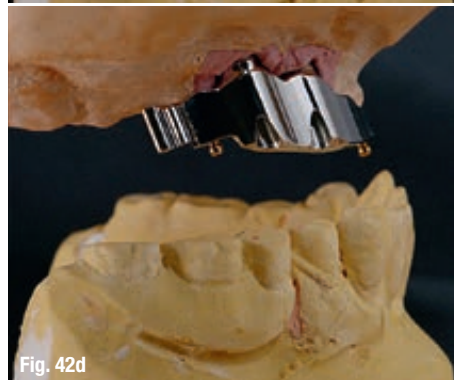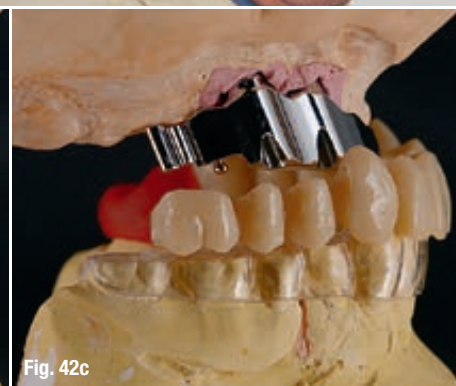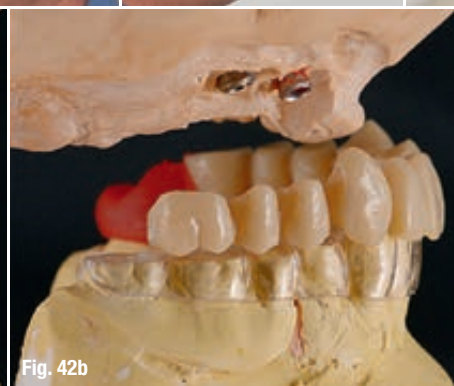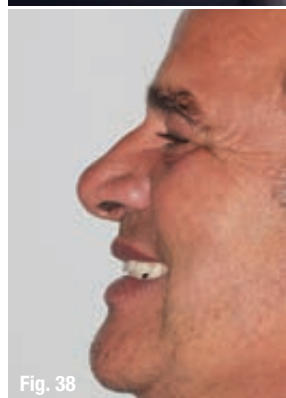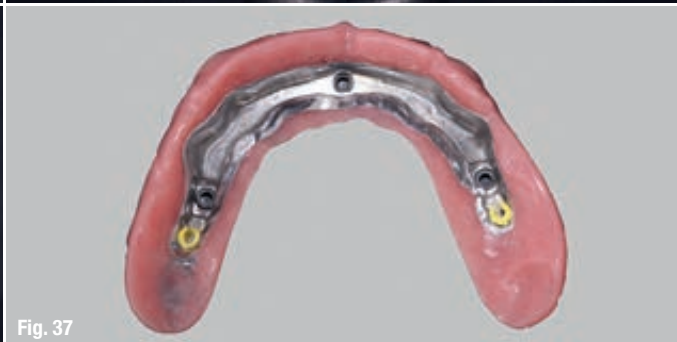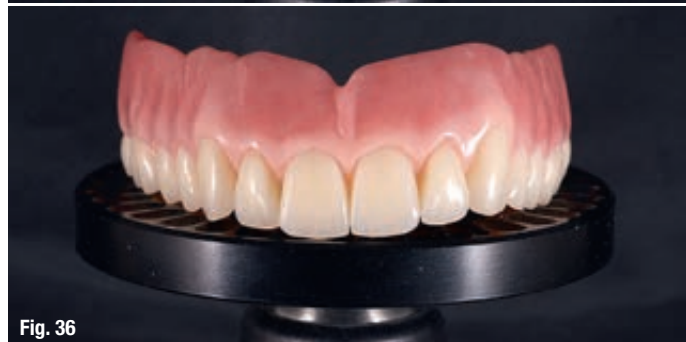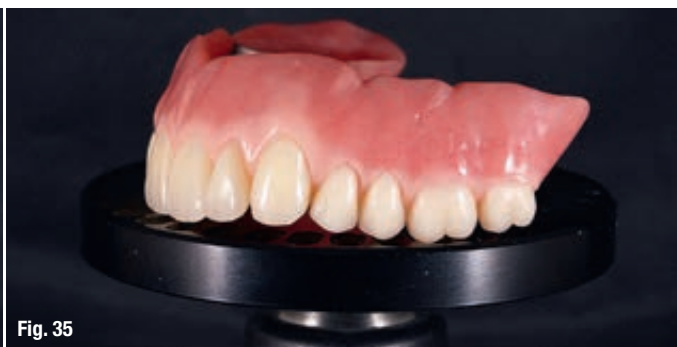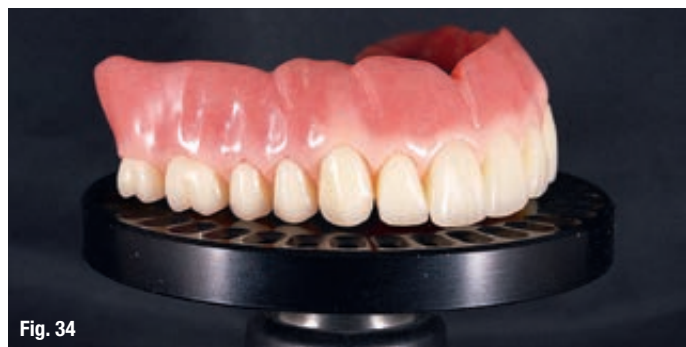Fig. 33



Rhein 83 Ot box inserted on the threaded Micro Spheres attachments, creating the housings for the retentive caps. The subsequent laboratory steps, the cast, the finishing, the polishing and the insertion of the retentive caps were performed to complete the frame (Figs. 12–18).

The secondary bar was embedded in the teeth assembly, using a silicone template previously made; the teeth were positioned one by one and adapted to make them engage with the retentions of the secondary bar. The flanges were modelled in the marginal gingival area using the Candulor modelling wax of medium hardness (Figs. 19–24).

An oral try-in of the work was done by screwing the primary bar and then inserting the prosthesis mounted on the secondary bar for a final test before the resin curing to verify the stability, retention, chewing, phonetic and support of the lips. A frontal, left and right side photograph were taken in order to carefully examine the harmony of the facial tissues (Figs. 25–27).

The model was prepared for the muffle technique by bathing it in water at a temperature of about 35 degrees. The base of the muffle was produced with a hard plaster. The flange models and the teeth were protected with a 90 Shore hardness silicone before completing the filling of the muffle with the hard plaster muffle before final hardening at 50 bar (Figs. 28–30).

After 60 minutes, the muffle was put in boiling water to open the mould. The whole surface was degreased by vapour and immersed in water at 35 degrees for 10 minutes. Once the retentions of the teeth were isolated and prepared, the flanges were produced by stratifying the Aesthetic Candulor resinous masses with a colouring of 53 for the collar edges and 34 for the fixed gingiva, and an intense red to characterise the alveolar mucosa (Figs. 31–33).

After the resin was finished, the muffle was closed and locked in a press bar at 80 bar; the subsequent polymerisation of the resin was performed at 50 degrees for 20 minutes at 3 atmospheres. At the end, the muffle was opened and the prosthesis was finished and polished.

The laboratory caps were replaced with the Rhein 83 'extra soft' yellow Ot cap Micro caps and the work delivered. In co-operation, the team carried out the final checks in the oral cavity paying attention to the stability, chewing and phonetics. The patient was instructed to use the prosthesis and to clean it by using primer bar cleaners and brushes with detergents for the prosthesis (Figs. 34–37).

Conclusions

The patient was satisfied with the performance received from the whole team. Within a few hours of delivery, she reported having good phonetics, very good chewing efficiency and finally noticed a good harmony of her face. After 6 months of delivery, the patient still looked happy and smiling for the successful rehabilitation (Figs. 41 & 42)

This is our team's goal: 'Rehabilitate the chewing function by combining aesthetics that in our day seems to have become the primary problem for our patients'.

contact



Dr Francesco Benvenuto graduated in 2003 at the University of Brescia. Faculty of medicine degree in dentistry. He undertook an internship at the University Clinic. His experimental thesis on microinfiltration of fiber pins with Prof. Cerutti was published in IADR (International Academy Dental Restorative). He frequents the conservative and endodontic department as a tutor where he is performing cases using the surgical microscope. SIE partner (an Italian endodontics company) is a student interested

in orthogonal and surgical and restorative aesthetic endodontics, attending numerous courses and congresses. ITI (International Team of Implantology) is dedicated to the periodontal implant and regenerative surgery with the attention to implant replacement of individual dental elements and soft tissue management with periodontal plastic techniques. Annual course with Prof. Zucchelli in clinical and surgical periodontology and mucogingival aesthetics.

S.D.A. Studi Dentistici Associati S.r.l.
Calcinatè BG: www.essedia.it



Giorgio Poma, dental technician graduated in 1999 at the Leonardo da Vinci Professional Institute for Dental Technology in Bergamo. In 1999 he attended the 'Total Prosthetic Complete Method' course at the Ivoclar Center in Naturno with the Speaker Tocco Antonio. Since 2009 he has worked as an employee at the S.D.A. Studi Dentistici Associati S.r.l and specialises mainly in total and removable dentures. From 2013 to 2015 he participated in various courses organized by Candulor with the speaker

Odt. Ivano Bortolini. In 2016 he participated in the course organised by Merz Dental with rapporteur Odt. Giorgio Garuffo. He attends the course 'The Implant Support Facility' organised by Odt. Carlo Borromeo. Participate in Basic and Master courses at Rhein'83. At the end of 2016 he started a collaborative relationship with Rhein'83 where he realised for the first time in Bologna at the course 'Modern techniques in removable prosthesis, Cad Cam and implantology master course' addressed to Dental Technicians and Dental Professionals. Since 2017 he has been working as an employee at the Techno Dent Laboratory of Calcinatè (BG). He collaborates with Dentistry in the province of Bergamo, Brescia, Monza Brianza and Catania.

Publication on 'Teamwork Clinic' of June 2016 entitled 'Overdentures on distal bars with micro threaded retentions'.

Laboratorio Techno Dent S.r.l.
Calcinatè (BG)
giorgio.poma@essedia.it