



The Remaking of a Removable Prosthesis Using New Techniques

Dr. Luca Ortensi, DDS

Co-authors: Gianni Ortensi, MDT,

Marco Ortensi, MDT,

Michael Renzi, MDT,

**Dr. Ortensi
will lecture at
Spectrum day Chicago
on Feb 26, 2016**



Fig. 1

Fig. 2

Figs. 1 to 3 — The patient's face at day 1: there is a reduction of the vertical dimension with increased perioral wrinkles and lack of visibility of the upper teeth in rest position. The smile seems discordant and unpleasant.

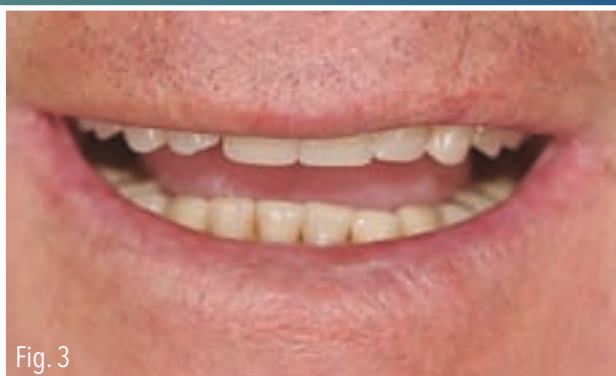

Fig. 3

Fig. 4 — The evaluation of the face in the sagittal view and the study of the lateral radiograph shows a lateral mesocephalic musculoskeletal type with reduced risk of overload bite forces.

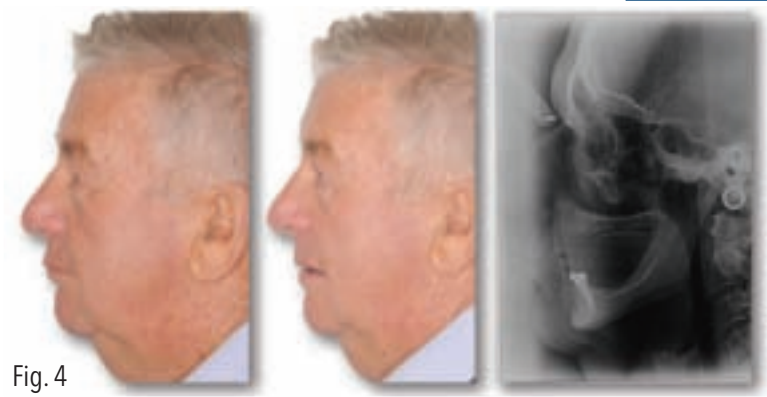

Fig. 4

Figs. 5 and 6 — Old prostheses which no longer have the ideal characteristics of aesthetics and function

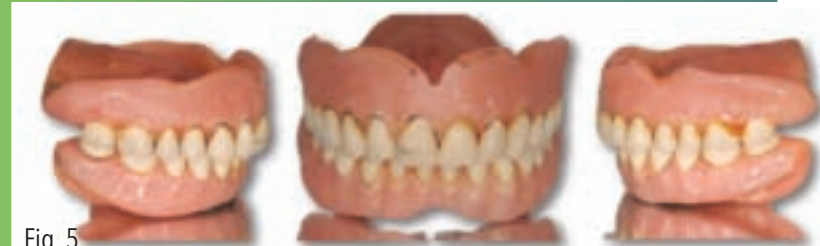

Fig. 5

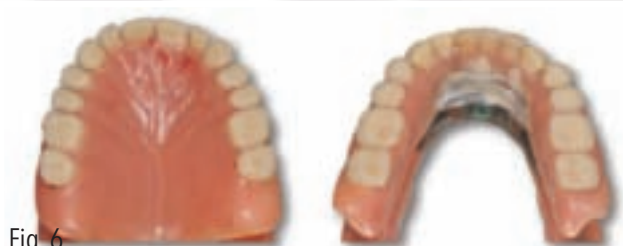

Fig. 6

More and more patients, today, arrive to the dental practice with obsolete fixed or removable prosthesis over implants. These prostheses show evidence of deteriorating aesthetics and/or function, which are mostly due to them losing their ideal characteristics, rather than the implants losing their osseointegration.

We can, therefore, conclude that the implant osseointegration, and its surgical therapy, have better durability and longevity than the prosthesis. This concept is even more true for overdentures, where the prosthetic components are subject to mechanical wear.^{1,2,3}

The purpose of this article is to show, by describing a case, how to perform

the reconstruction of a prosthetic overdenture taking advantage of the pre-existing implants, by applying new technologies available in modern restorative dentistry.

Description of the case:

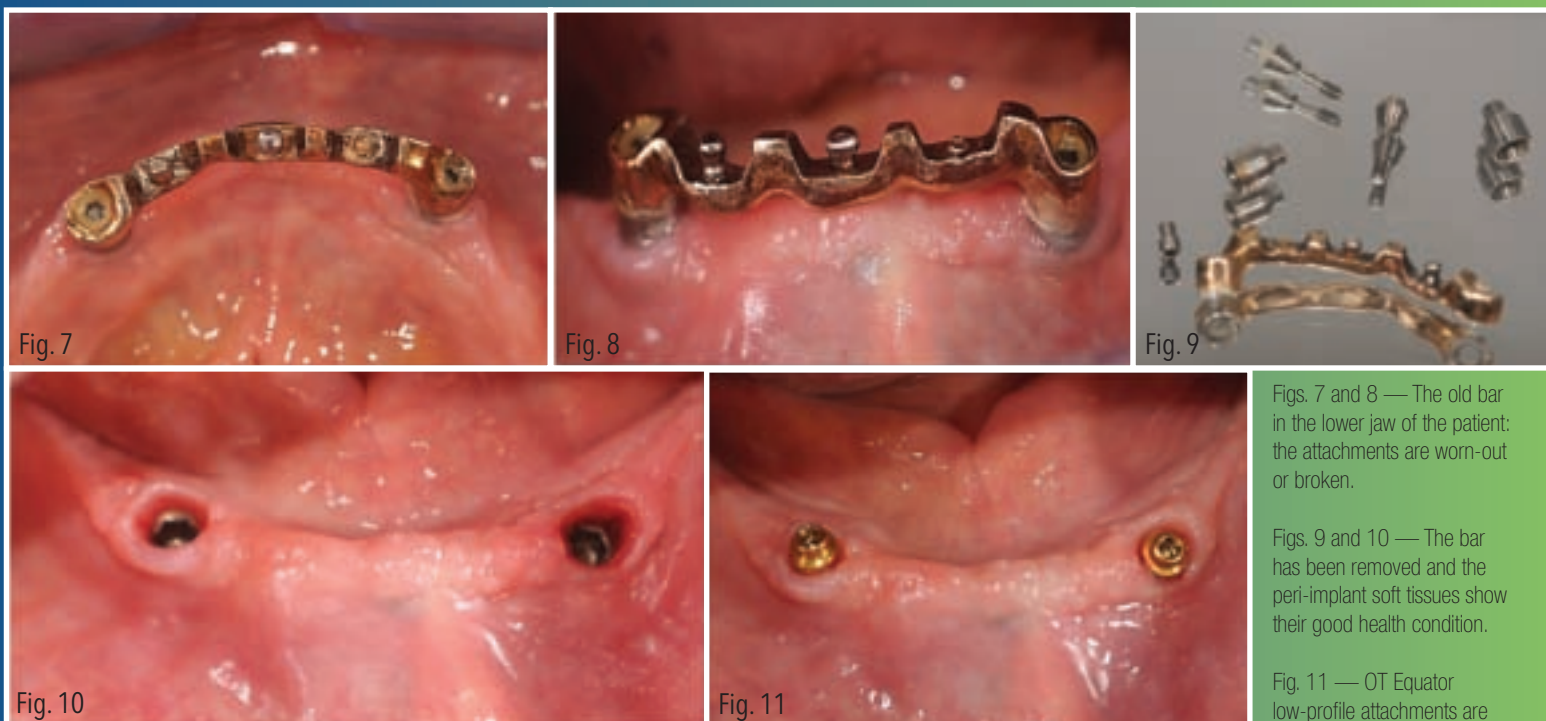Introduction

A 70-year old patient arrived to the practice complaining about diminished masticatory capacity, and the loss of retention of both his removable dentures. He also requested improving his smile and facial aesthetics, stating he was dissatisfied with the color and visibility of his teeth, even with the most stressed facial expressions.

Anamnesis did not show any

pathology incompatible with dental treatment, and demonstrated the patient was in general good health and classified as ASA1.

Physical examination of the face showed a reduction of the vertical dimension, with a widening of the nasolabial folds, and diminished tone of the perioral soft-tissue, with a generalized deterioration of all the facial aesthetic parameters. The patient's smile seemed non harmonious due to dental wear and the inclination of the occlusal planes, which affected general aesthetics (Figs. 1-2-3). The evaluation of the face in the sagittal view, and the study of the lateral radiography, showed a mesocephalic musculoskeletal situation with reduced risk of excessive bite-loads.



Figs. 7 and 8 — The old bar in the lower jaw of the patient: the attachments are worn-out or broken.

Figs. 9 and 10 — The bar has been removed and the peri-implant soft tissues show their good health condition.

Fig. 11 — OT Equator low-profile attachments are screwed on the implants, used as multi-unit abutments.

The lateral cephalometric is a valuable diagnosis tool that the authors consider as pivotal in formulating a proper treatment plan in a complex prosthetic rehabilitation. This x-ray examination allows studying the hard and soft tissues of the the patient's face, in particular, the relationship between the maxilla, the spatial position of the upper central incisor and the philtrum. It is also possible to identify, with an appropriate and simple cephalometric analysis, the musculoskeletal classification (Fig. 4).⁴

During the intraoral clinical examination, we observed incongruous removable dentures in both arches (Fig 5-6). The upper arch had a full-removable denture, while the lower jaw had a full-removable denture supported by two implants located in the canine region, which were connected by a casted bar. The bar looked worn-out in all its retentive components (Figs. 7-8). The artificial teeth of both prostheses showed obvious signs of wear of a

magnitude such, that it was impossible for the patient to maintain a stable and repeatable maxillomandibular relationship. Even removing the dentures from the mouth and repositioning them manually, the search for a stable occlusion was impossible.

After removing the prostheses and the bar, we noticed that the peri-implant soft tissues were in good condition. The implants had a considerable degree of divergence that, thanks to the new technologies available, we would try to overcome with the new prosthetic design (Figs. 9-10).

At this preliminary stage, we screwed the low profile OT Equator attachments (Rhein 83, Bologna, Italy) directly on the implants, to be used as multi-unit abutments, in order to overcome the divergence between the implants. With OT Equator it is possible to design a totally-passive bar without tension, as required by the scientific literature in this subject.⁵

This way, in a first provisional stage, the patient reacquired a satisfactory prosthetic stability (Fig. 11).

Clinical and laboratory procedures.

In this early clinical stage, we took the preliminary impressions with alginate. This phase should be paid close attention to, as it is essential for fully recording the anatomy of both jaws. We normally use a high-precision alginate applied in two stages: we take a first impression with a high-consistency alginate. Then, we dry it, remove the undercuts with a scalpel, and reline the impression with the same alginate, but more fluid, in order to read all the details of the anatomical tissues.

From the preliminary impressions, we make two extra-hard plaster models on which the limits of the custom tray are drawn. The authors believe that the design of this line is one of the most important aspects of this



Fig. 12

Fig. 12 — First stone models obtained from the extended alginate impressions: All the buccal anatomy necessary for the construction of the prosthesis must be visible.

Fig. 13 — The individual trays: their extension reflects the line traced on the preliminary models.

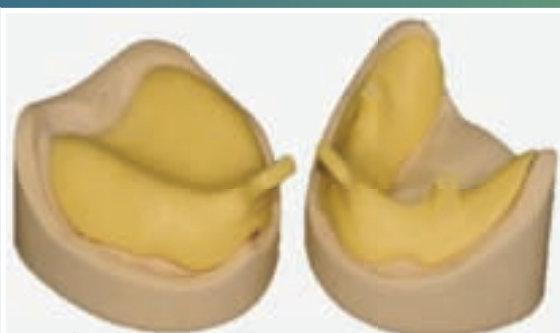

Fig. 13

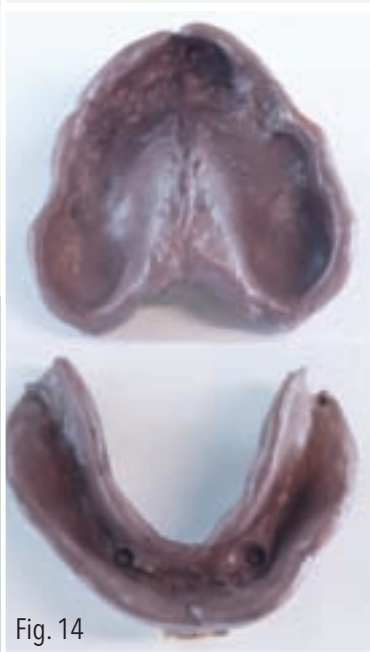

Fig. 14

Fig. 14 — Definitive polysulfide impressions.

Fig. 15 — Sagittal view of the patient: relationship between the wax rims and the perioral soft tissues.

Fig. 16 — Evaluation of the front teeth set-up; side visual.

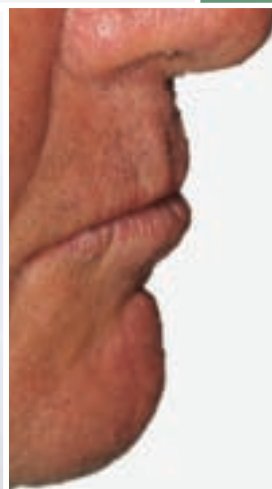


Fig. 15

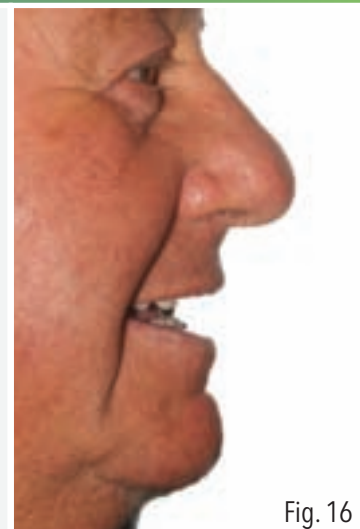

Fig. 16

initial phase, which can determine the success of the therapy. Both the dentist and the dental technician, in equal measure, must know the anatomical components and the muscular dynamics that underlie an ideal prosthetic design; not relying solely on the presence and the retention offered by the implants (Fig. 12).

The individual upper and lower trays, are constructed in self-curing acrylic resin after the undercuts have been removed with soft wax. The edges of the trays have an average thickness of 2mm. In the sublingual area and distally to the zygomatic areas, higher thicknesses of the edges (around 3-4 mm) are allowed (Fig. 13). The dentist must verify the correct extension of the

bases in the mouth, by using a silicone fit-checker paste.

The final impressions are recorded in polysulfide, after the functional adaptation of the impression trays with different consistency pastes. In order to achieve good functional trays, it is mandatory to activate the muscles of the lips, tongue and cheeks, through actions performed by the patient under the careful guidance of the clinician, which will also make a slight traction on the soft tissues, to record the limit of the frenula (Fig. 14).

Once the new models from the final impressions are produced, the dental technician builds two wax rims with a resin base, to record the maxillomandibular relationship, and

to determine the aesthetics and the functional volumes, necessary for a precise assembly of teeth.

The dentist checks the stability of the upper rim before proceeding with its functionalization. Next, using a Fox fork, he defines the parallelism between the plane of Camper and the occlusal plane of the upper wax rim. Frontally, always with the same tool, he looks for the alignment of the upper rim and the pupil's line, in harmony with the face. We recall that, in most clinical situations, the pupil's line is the reference line for aesthetics.

The midline is marked on both rims. The median facial line crosses the glabella, the tip of the nose, the philtrum and the chin tip; and should

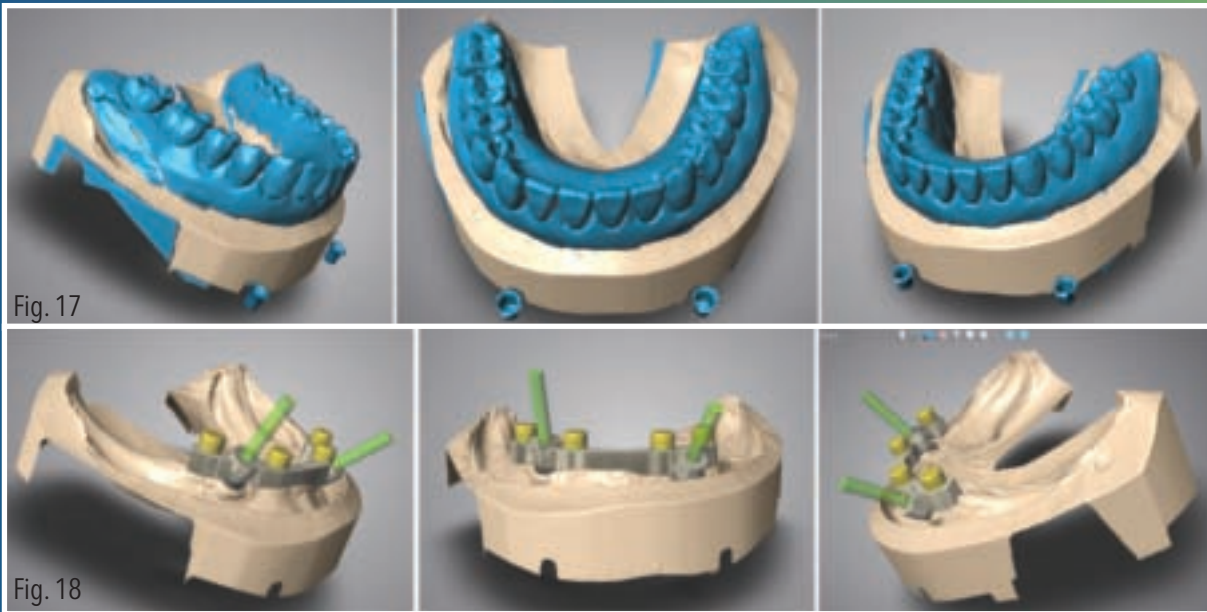


Fig. 17

Fig. 18

Fig. 17 — Completed set-up of the lower teeth acquired through a digital scanner.

Fig. 18 — Computer-aided design of the bar.

be perpendicular to the pupil's line forming, thus, a hypothetical "T".

If the tip of the chin or nose deviates from the principal axis, and the median line doesn't appear adequate for a correct mounting of the teeth, the dentist should consider only the philtrum as a reference for positioning the aesthetics of the anterior group.⁶

The vertical dimension of the occlusion is found with the functionalization of the rims through the phonetic pronunciation of the phoneme "M", to search for the vertical dimension at rest; the phonemes "F, V and S" for the investigation of the occlusal vertical dimension. Later we seek a stable and repeatable mandibulocranial relationship through the manipulation of the jaw.

The dentist must finish the clinical stage of functionalization of the rims checking their effect on the sagittal plane over the soft perioral tissues: anatomical area of the philtrum and nose-chin distance.⁷ We recall that much of the final aesthetics of the face will depend on this clinical procedure (Fig. 15).

Once the functionalized rims are back on the final models, we begin with the assembly of the front teeth. Taking as a reference the median line, we create an opening on the upper wax to make room for the corresponding tooth. The same approach is also used for the lower arch being careful to create correct overbite / overjet ratio.

Only the anterior teeth set-up is delivered to the clinician for the appropriate try-ins: the dentist performs the phonetic tests to verify the correctness of the vertical dimension and of the spatial position of the front teeth. The patient is asked to speak and / or count. The clinician also verifies the support of the perioral soft tissue and their relationship with the artificial teeth both in a frontal and sagittal view. (Fig. 16). Also the smile is evaluated, focusing on the proper exposure of the upper teeth and their alignment. Some little and intended imperfections of the incisors, like small rotations or light abrasions of the dental surfaces can make the smile even more natural.

The same operations and the same tests are made after the complete assembly of the teeth. This phase should be done, in particular, regarding the maxillomandibular relationship. The patient must not have slippage due to interference during the maximum intercuspation: it must be eliminated at this stage, by the clinician. When interferences are too numerous, it is advisable to provide the dental technician with a hard silicone bite for the replacement of the models in the articulator.

At the end of the clinical try-ins, once the intended aesthetic and functional objectives are achieved, the dental technician works on the lower wax for the production of the bar (Fig. 17). The inferior set-up, with its volumes, is acquired with a scanner. Subsequently, the underlining bar is designed with a CAD system, and then the file is sent to the milling center. The bar is manufactured in titanium, and has the threads for screwing the ball attachments in the intended areas (Figs. 18-19), where there is enough space available, it is easily assessable with the CAD software by means of

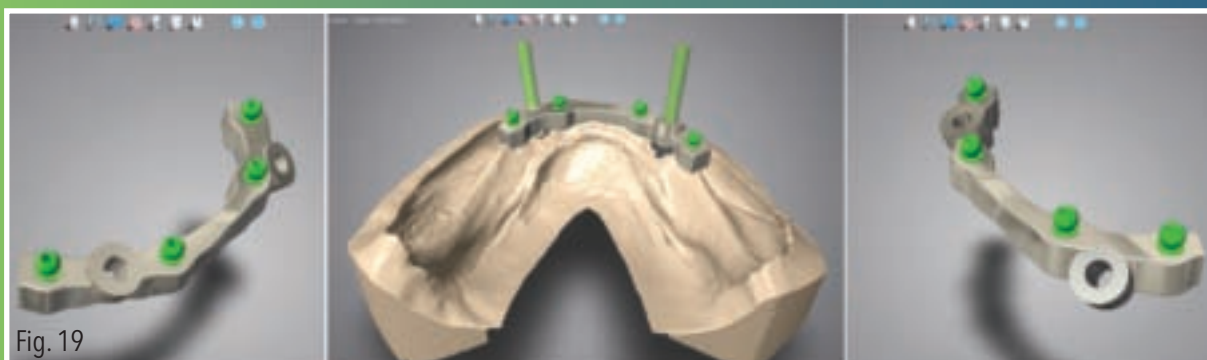
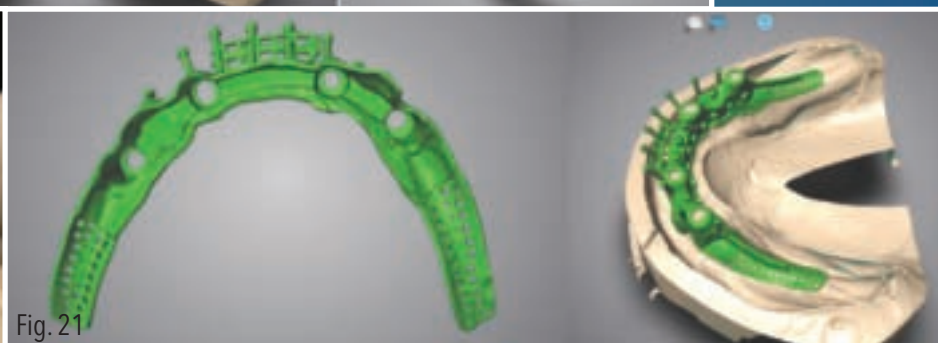

Fig. 19 — Computer-aided design of the bar: focus on the spherical attachments.

Fig. 20 — Positioning of the spherical attachments on the titanium bar obtained by a Cam milling.

Fig. 21 — Digital design of the counterbar as thin as possible.



the transparencies of the digitalized set-up. The bar has been designed over the Ot Equator low-profile attachments: the space available, between the attachment and the bar, is compensated by the positioning of an acetalic ring called Elastic Seeger

(Rhein 83, Bologna, Italy) that engages the undercuts of the attachment, and locks the bar even with divergent implants.⁸ The Elastic Seeger, once tightened by the locking screw, creates a passive monobloc between bar and Ot Equator attachment (Fig. 20).

The dental technician proceeds with the production of a counterbar, designed virtually through the aid of the CAD software. Its production is made with laser-melting technology that allows obtaining a precise counterbar onto which the acrylic

The ADAM Centre

Ancaster Design and Milling 1-905-841-2332
www.AdamCentre.com - info@AdamCentre.com

3-D Scanning & Design

TRAINING

Learn from EXPERTS
with YEARS of
EXPERIENCE!

Call 905-841-2332

ZENOSTAR

Full contoured bridges & crowns
Ultimate Strength for Challenging Cases

Custom Abutments

- Hybrid custom abutment design
- Cost effective & time saving

Call Dave Dalgleish R.D.T.
Director - Consultant & Designer



Fig. 22

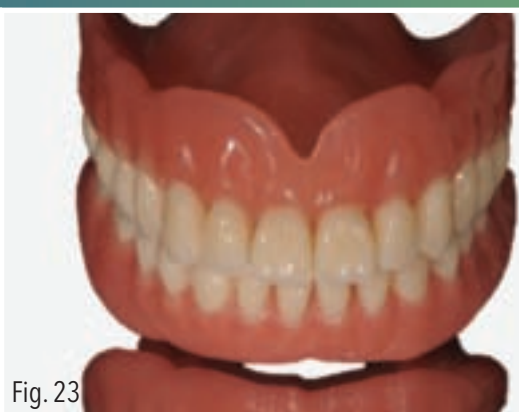


Fig. 23

Fig. 22 — Detail of the counterbar obtained by a process of laser-melting.

Fig. 23 — Prostheses finished and polished are sent to the dental office.

Fig. 24 — Detail of the bar and the completed prostheses.

Fig. 25 — The bar placed in the mouth: Please note the correct soft tissue relationship.

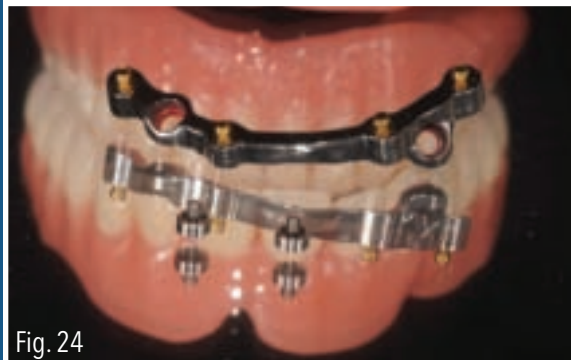

Fig. 24

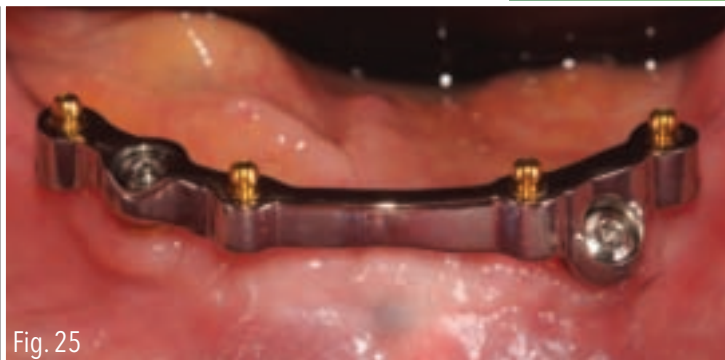

Fig. 25

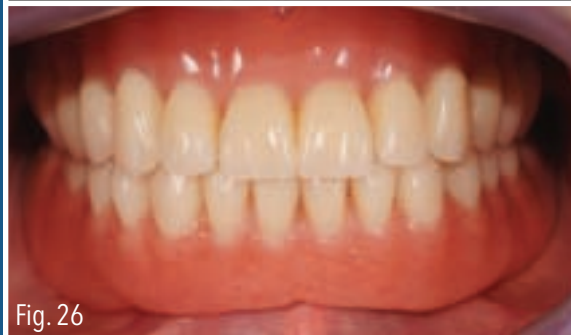

Fig. 26

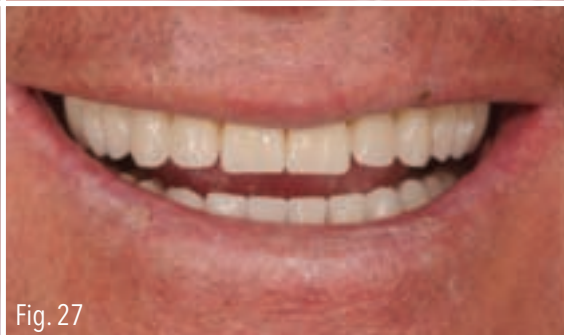

Fig. 27

Fig. 26 — The final prosthesis applied in the patient's mouth.

Fig. 27 — The smile of the patient with the final prosthesis inserted in the mouth.

resin adheres, thanks to the presence of a retentive surface (Figs. 21-22).

The technician completes the finishing of the prosthesis through the use of a silicone mold, inside a aluminum muffle. Before injecting the resin, the counterbar was treated with sandblasting (Al_2O_3), silicatization (ROCATEC, 3M-ESPE, St. Paul, MN, USA), silanization and coating with self-curing aesthetic opaque.

The prostheses and the bar are sent to the dental practice perfectly polished. The authors prefer a modeling of the prosthetic flanges that respects the anatomy, but that also allows the patient a simple cleansing of the prostheses (Figs. 23-24).

The bar is placed by the clinician in the mouth, and tightened to the implants with a predetermined torque, according to the implant specifications. The dentist has to assess that there are no areas of soft tissue compression, and that there is enough room for the passage of the specific cleaning tools (brushes and tufted floss). Note the parallelism of the attachments, which is synonymous of prosthetic retention and performance maintainability over time (Figs. 25-26).

Once the prosthetic therapy is finished, the patient shows an improved aesthetic. The perioral soft tissues appear tonic as a result of a good prosthetic support. There is a

reduction of the nasolabial folds, of the perilabial wrinkles, both frontally and laterally. The vertical dimension, which has been slightly increased, appears adequate and well-tolerated. During phonation and the dynamics of the smile, the patient shows natural-looking teeth, perfectly integrated into the face (Figs. 27-28).

Focusing on the lateral side, we can see how the nasolabial angle has the correct values, and the patient philtrum is well-supported by the prosthesis' flange (Figs. 29-30).

The last images show the authors' leading philosophy in designing and executing complex prosthetic treatments: the face is the guide for a



Fig. 28 — Patient's face after the treatment: the appearance looks improved.

Figs. 29-30 — The patient's face in lateral view: you can see how the nasolabial angle has the correct values and the patient has a philtrum supported by the prosthetic flange.


correct treatment and restoration of both the aesthetics and the function (9-10).

Conclusions

The current clinical case allows us to describe the construction of a removable prosthetic with implant retention. During the clinical and technical steps we have applied some of the most updated techniques that give us some clear advantages such as:

- The possibility to design the retentive bar over the implant digitally, while being able to control all functional aspects;
- The insertion of easily-replaceable retentive attachments, as a precaution in the event they wear-out over time;
- The possibility of creating passive structures over implants using a simple and effective protocol;
- The possibility of building more precise prostheses, and with better technical characteristics, in less time.

Certainly, we are still at the beginning of a technological evolution involving the entire dental world which is

already changing the way of dealing with complex restorative therapies. But, we must not forget that the health of the patient, and the scientific knowledge, are the milestones that guide us in any therapeutic act, and that even the latest technology should be at the dentist's service in order to achieve the above objectives. 

Bibliography:

Vercruyssen, M., Marcelis, K., Coucke, W., Naert, I. and Quirynen, M. (2010), Long-term, retrospective evaluation (implant and patient-centred outcome) of the two-implants-supported overdenture in the mandible. Part 1: survival rate. *Clinical Oral Implants Research*, 21: 357-365.

Attard, N. J., & Zarb, G. A. (2003). Long-term treatment outcomes in edentulous patients with implant overdentures: the Toronto study. *The International journal of prosthodontics*, 17(4), 425-433.

Katsoulis J, Brunner A, Mericske-Stern R. Maintenance of implant-supported maxillary prostheses: a 2-year controlled clinical trial. *Int J Maxillofac Implants* 2011; 26 648-56.

Sethi A, Kaus T. Practical implant dentistry: diagnostic, surgical, restorative and technical aspects of aesthetic and functional harmony. Quintessence Publishing, Chicago (2005).

Sahin, Saime, and Murat C. Çehreli. The significance of passive framework fit in implant prosthodontics: current status. *Implant dentistry* 10.2 (2001): 85-92.

Techno-clinical aspects of fixed removable prosthesis. Teamwork Media 2015.

Ortensi L, Stefani R, Ortensi G. Edentulous superior maxillary: choosing the proper implant supported prosthetic solution. *Spectrum Dialogue* Apr 02, 2015 ,Vol 14 , No 3

Stoumpins C, Kohal To splint or not to splint oral implants in the implant-supported overdenture therapy? A sistematic literature review. *J Oral Rehabil* 2011; 38: 857-869.

Avrampou M, Mericske-Stern R, Blatz MB, Katsoulis J. Virtual implant planning in the edentulous maxilla: criteria for decision making of prosthesis design. *Clin Oral Impl Res*. 2013; 24: 152-59.

Neves FD, Mendonca G, Fernandez Neto AJ. Analysis of influence of lip support in esthetics and selection of maxillary implant-supported prosthesis design. *J Prosthet Dent*. 2004; 91: 286-8