

Two implants supporting a mandibular overdenture to rehabilitate Cawood and Howell Class V and VI patients: A proof-of-concept study

Abstract

Objective

The objective of this study was to present the preliminary results one year after loading for a single cohort of Cawood and Howell Class V and VI patients rehabilitated with a mandibular overdenture supported by two implants using a novel low-profile retention system.

Materials and methods

Completely edentulous individuals, aged 18 years or older at the time of implant placement, presenting as Class V or VI according to Cawood and Howell were enrolled and treated with two implants, low-profile direct implant overdenture attachments and a removable complete mandibular denture. Outcome measures were success rates of the implants and prosthesis, complications, marginal bone levels, bleeding index, plaque index and patient satisfaction (Oral Health Impact Profile).

Results

A total of 18 Osstem TSIII implants (diameter: nine regular and nine mini) were placed in nine consecutive edentulous patients (seven female and two male) presenting with Cawood and Howell Class V ($n = 6$) or VI ($n = 3$) mandibular atrophy. The average age of the patients was 68 (range: 53–77). The participants were followed up for a minimum of one year (mean: 18.2 months; range: 12–22) after definitive loading. No participants dropped out, and no deviation from the original protocol occurred. At the one-year follow-up, no implants or prosthesis had failed, resulting in cumulative implant and prosthetic survival rates of 100%. No biological or technical complications occurred during the follow-up, resulting in cumulative implant and prosthetic success rates of 100%. At the one-year follow-up, the mean marginal bone loss was 0.39 ± 0.15 mm. The Oral Health Impact Profile summary scores demonstrated a significant decrease one month after prosthesis delivery ($p = 0.0000$) and between the one-month and one-year follow-ups ($p = 0.0005$), after retention system replacement. At the one-year follow-up, the bleeding index was 8.3% and the plaque index was 9.7%.

Conclusion

Within the limitations of this study, a mandibular overdenture supported by two implants can be considered an effective and predictable option

Erta Xhanari,^{a,b} Roberto Scrascia,^c Blerina Kadiu^b
& Marco Tallarico^{a,d}

^a Aldent University, Tirana, Albania

^b Private practice, Tirana, Albania

^c Private practice, Taranto, Italy

^d Osstem AIC, Italy; private practice, Rome, Italy

Corresponding author:

Dr. Erta Xhanari

Rr. Sulejman Delvina, 19
1001 Tirana
Albania

info@ertaxhanari.com

How to cite this article:

Xhanari E, Scrascia R, Kadiu B, Tallarico M.
Two implants supporting a mandibular overdenture
to rehabilitate Cawood and Howell Class V and VI
patients: a proof-of-concept study.
J Oral Science Rehabilitation.
2017 May;3(1):24–31.

for successful treatment of patients presenting with Cawood and Howell Class V or VI mandibular atrophy. After a short period of accommodation, it is recommended to replace the conventional retention caps with stronger ones to improve overdenture stability and thus patient satisfaction.

Keywords

Dental implant, overdenture, retention system, atrophic mandible, edentulous.

Introduction

Edentulism can lead to significant functional impairment and unfavorable esthetic and psychological changes in patients. Problems include restrictions in diet, speech impairment, loss of soft-tissue support and decreased vertical dimension.¹ The conventional method for treating edentulism is to provide complete dentures. However, progressive and irreversible loss of basal bone may lead to incrementally increasing difficulties for the denture patient, especially in relation to the mandible, creating problems like loss of retention and stability, hyperplasia and ulceration of the underlying mucosa, discomfort and pain, and impaired psychosocial functioning.² A removable implant-supported prosthetic design offers better retention and improves oral function and patient satisfaction compared with a conventional complete denture.^{3,4} Furthermore, in the mandible, it is possible to load implants immediately without increasing the risk of implant failure.⁵⁻⁷ Implant overdentures have been the subject of several clinical trials and systematic reviews, which have demonstrated them to be an effective and clinically predictable approach to obtaining improved retention and hence masticatory function and patient satisfaction.^{8,9}

Implant overdentures can be divided into two subcategories:¹ implant-retained, mucosa-supported overdentures (retained by different abutment or bar designs); and overdentures fully supported by implants.^{10, 11} In contrast to a mucosa-supported overdenture, an overdenture that is rigidly anchored to a milled bar supported by four interforaminal implants prevents rotational movement of the prosthesis, reducing possible jaw resorption and consequently possibly also the incidence of prosthodontic maintenance.¹⁰ In patients with an altered skeletal maxillomandibular relationship and severe bone atrophy (Cawood and Howell Class V and VI),¹² an overdenture fully supported by four implants

has been shown to be a predictable method for long-term treatment of edentulous patients.¹⁰ Nevertheless, limitations such as financial restrictions sometimes prevent the placement of a sufficient number of implants to accommodate a fixed dental prosthesis and therefore an alternative for edentulous patients with compromised oral function is required.

The purpose of this proof-of-concept study was to present the preliminary results one year after loading for a single cohort of Cawood and Howell Class V and VI¹ patients rehabilitated with a mandibular overdenture supported by two implants using a novel low-profile retention system. This study followed the Strengthening the Reporting of Observational Studies in Epidemiology reporting guidelines.¹³

Materials and methods

This prospective case series study was carried out in accordance with the Declaration of Helsinki of 1975, as revised in 2008. All of the participants were consecutively enrolled and treated in two private centers after being informed about the nature of the study and providing their written consent. Any healthy edentulous individual aged 18 years or older at the time of implant placement with Class V or VI mandibular atrophy according to Cawood and Howell,¹ assessed by a cone beam computed tomography scan (**Fig. 1**), was considered eligible for the study. Exclusion criteria were general contraindications to oral surgery, pregnancy or nursing, intravenous bisphosphonate therapy, alcohol or drug abuse, heavy smoking (≥ 20 cigarettes/day), radiation therapy to the head or neck region within the last five years, parafunctional activity, untreated periodontitis, and allergy or adverse reactions to the restorative materials.

All of the patients received a new conventional removable denture before implant place-

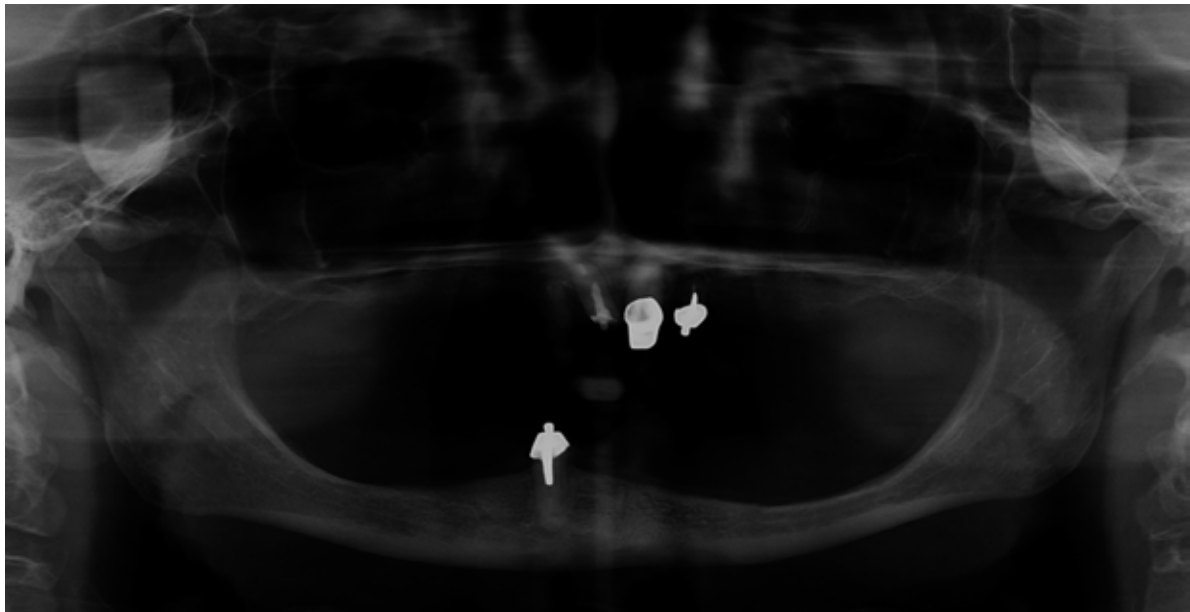


Fig. 1

Fig. 1
Preoperative radiograph.

ment, according to the respective functional and esthetic requirements. Impressions were taken, a master cast was poured, occlusal registrations were taken, and a wax-up was prepared and tried in. The conventional removable denture was delivered one week before the surgery and used as a guide for the implant placement. On the day of the surgery, a single dose of an antibiotic (2 g of amoxicillin or 600 mg of clindamycin if allergic to penicillin) was administered 1 h before implant placement and continued for six days after surgery. Immediately before surgery, the participants rinsed with a 0.2% chlorhexidine mouthwash for 1 min. Local anesthesia was administered with a 4% articaine solution with 1:100,000 epinephrine (Ubistein, 3MESPSE, Seefeld, Germany). Minimally invasive mucoperiosteal flaps, without releasing incisions, were elevated. Then, the implants were placed in the interforaminal region of the mandible according to a one-stage approach.¹⁴ Each participant received two implants (Osstem TSIII, Osstem, Seoul, South Korea), placed according to a previously published surgical protocol, recommended by the manufacturer, in order to achieve an insertion torque of at least 35 N cm.¹⁵ After surgery, the patients were instructed to avoid brushing and trauma at the surgical site. A cold and soft diet was recommended for ten days. Smokers were recommended to avoid smoking for three days postoperatively, and oral hygiene instructions were given. Analgesics (600 mg of ibuprofen) were prescribed as needed. Sutures (if present) were removed after ten days.

The prosthetic procedures were begun eight weeks after implant placement. The healing abutments were unscrewed, the implant connections were cleaned and the newest low-profile direct implant overdenture attachments (OT Equator, Rhein83, Bologna, Italy; **Fig. 2**) were screwed on to the implants, using the OT Equator square screwdriver (Rhein83), with a torque range of 22–25 N cm. The cuff heights ranged from 0.5 to 7.0 mm, depending on the height of the transition zone of each implant, easily measured using the color-coded millimeter Cuff Height Measurer Gauge (Rhein83) after healing abutment removal. Afterward, spaces to accept the female housing steel cage were prepared in the fitting surface of the new removable complete mandibular denture. Silicone protective discs (Rhein83) were placed over the OT Equator attachments (**Fig. 3**). Extra-soft (yellow, 600 g) or soft (pink, 1,200 g) retentive caps were placed in to the female steel housing, attached to the OT Equator and finally fixed to the denture using self-cured acrylic resin while the patient held the dentures in centric occlusion, chairside. After complete polymerization, the denture was picked up and silicone discs removed. Acrylic excess was trimmed and the denture was refined and polished (**Fig. 4**). One month after prosthesis delivery, the retentive caps were replaced with a stronger type (violet, 2,700 g; **Fig. 5**). The occlusion was developed to deliver a lingualized occlusion in centric relation with balanced contacts during function, avoiding any premature contacts (**Figs. 6a & b**).

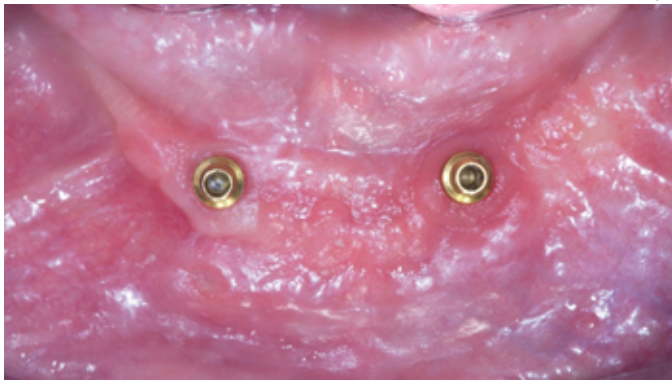

Fig. 2

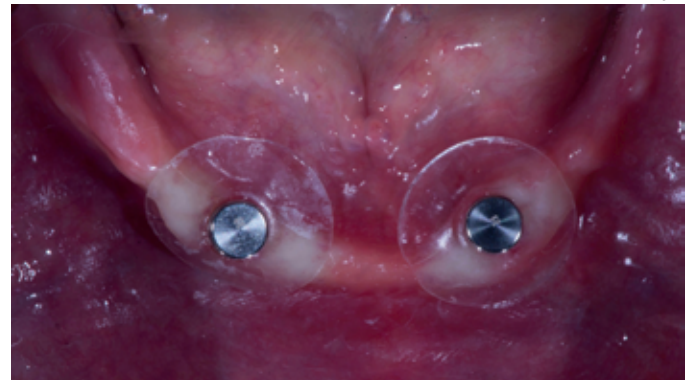

Fig. 3

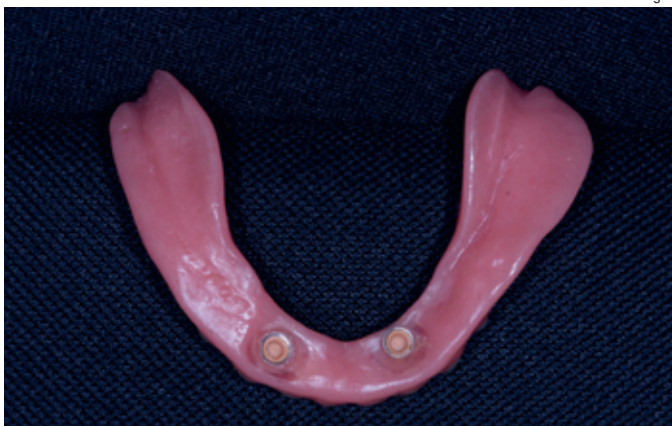

Fig. 4

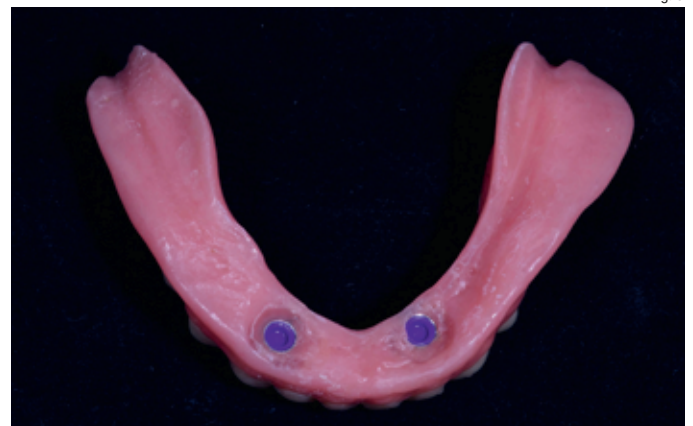

Fig. 5

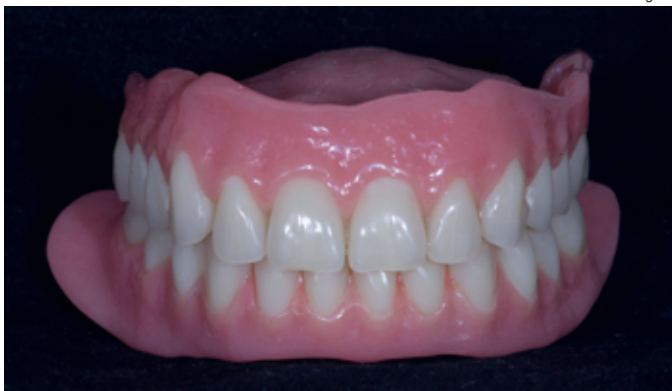

Fig. 6a

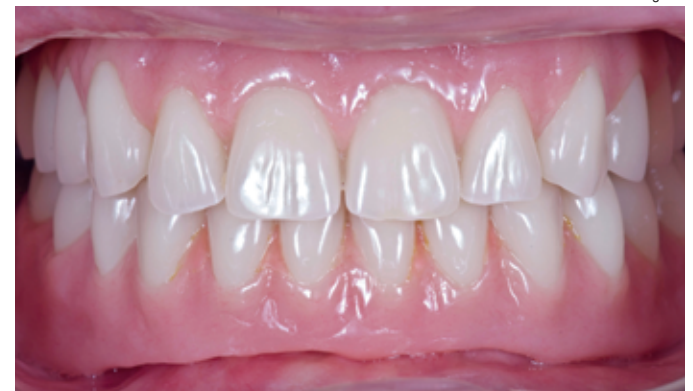

Fig. 6b

Nevertheless, when the opposing arch was a removable complete denture, the over-jet was left purposely broad, from 2 to 5 mm in order to avoid interferences during function. Instructions were given to the patients, and recall visits were scheduled for occlusal adjustments and oral hygiene quality control every six months and for retentive cap replacement every year (Figs. 7 & 8).

Outcome measures

The primary outcome measures were the following:

- Success rates of the implants and prosthesis: An implant was considered a failure if it pre-

sented with any mobility, assessed by tapping or rocking the implant head with the metallic handles of two instruments, progressive marginal bone loss or infection, and any mechanical complications rendering the implant unusable, although still mechanically stable in the bone. A prosthesis was considered a failure if it needed to be replaced with another prosthesis.

- Complications: Any biological (pain, swelling, suppuration, etc.) and/or mechanical (screw loosening, fracture of the framework and/or the veneering material, etc.) complications were evaluated.

Fig. 2

Clinical view after placement of the two implants (Osstem TSIII) according to a one-stage protocol.

Fig. 3

Silicone protective discs before denture rebase.

Fig. 4

Soft retentive caps in the female steel housing.

Fig. 5

Stronger retentive caps.

Figs. 6a & b

View of the definitive prosthesis.

Table 1

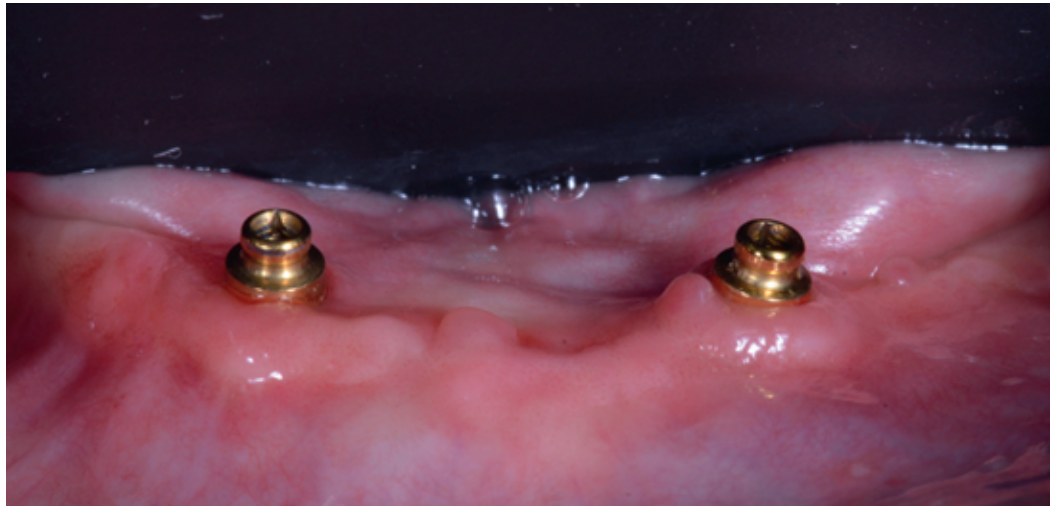Patients and implant outcomes.

Fig. 7

Close-up view of the low-profile attachments (OT Equator).

	Age (years)	Sex	Smoking	Implants	Implants 8.5 mm length	Implants 10 mm length	Implants 3.5 mm wide	
Patient 1	67	F	0	2	0	2	0	
Patient 2	74	F	0	2	0	2	2	
Patient 3	77	F	0	2	0	2	2	
Patient 4	71	F	0	2	0	2	0	
Patient 5	66	F	0	2	0	2	0	
Patient 6	64	M	0	2	0	2	0	
Patient 7	53	F	0	2	0	2	2	
Patient 8	72	M	0	2	2	0	2	
Patient 9	68	F	0	2	0	2	1	
Total		7F/2M		18	2	16	9	
Mean ± SD								

MBL = Marginal bone loss; OHIP = Oral health impact profile; T0 = Baseline; T1 = One month after definitive prosthesis delivery; T2 = One year after definitive prosthesis delivery; BI = Bleeding index; PI = Plaque index; SD = Standard deviation.

**Fig. 7**

– Marginal bone levels: The levels were assessed using intraoral digital periapical radiographs (Digora Optime, SOREDEX, Tuusula, Finland; photostimulable phosphor imaging plate, size 2, pixel size of 30 μ m, resolution of 17 lp/mm) at implant placement (baseline) and one year after loading. Intraoral radiographs were taken with the paralleling technique by means of a periapical radiograph with a commercially available film holder (Rinn XCP, Dentsply Rinn, Elgin, Ill., U.S.). The radiographs were accepted or rejected for evaluation based on the clarity of the implant threads. All readable radiographs were uploaded to an image analysis software package (DfW 2.8, SOREDEX) that was calibrated using the known length or diameter of the dental implants and displayed on a 24 in. LCD screen (iMac, Apple, Calif., U.S.)

and evaluated under standardized conditions (ISO 12646:2004). The marginal bone levels were determined from linear measurements performed by an independent calibrated examiner on each periapical radiograph, from the mesial and distal margin of the implant neck to the most coronal point where the bone appeared to be in contact with the implant.

– Patient satisfaction with function and esthetics was assessed using a scale of 1–10, where 10 = fully satisfied, 5 = satisfied and 1 = not satisfied. Quality of life was assessed by the Oral Health Impact Profile (OHIP-21) questionnaire, which was completed by the participants. The questionnaire consists of seven subscales (functional limitations, physical pain, psychological discomfort, physical disability, psychological disability, social disability,

Table 1

	Implants ≥ 4 mm wide	Failed implant	Failed prosthesis	MBL (mm)	OHIP T0	OHIP T1	OHIP T2	BI	PI
	2	0	0	0.20	69	38	26	1	0
	0	0	0	0.30	78	35	21	2	2
	0	0	0	0.30	83	29	21	0	0
	2	0	0	0.50	68	30	16	0	1
	2	0	0	0.30	65	22	22	0	0
	2	0	0	0.70	80	28	24	3	4
	0	0	0	0.30	74	34	22	0	0
	0	0	0	0.40	72	29	18	0	0
	1	0	0	0.50	76	24	18	0	0
	9	0	0					8.3%	9.7%
				0.39 ± 0.15	74 ± 6	30 ± 5	21 ± 3		

ity, and handicap) with two to four questions each. Participants chose from five possible responses for each question as follows: never, hardly ever, occasionally, fairly often and very often. Items were scored on a five-point ordinal scale ranging from 1 (never) to 5 (very often). Lower OHIP total scores are suggestive of improvement in oral health-related quality of life. The questionnaire was administered before treatment and one month and one year after definitive prosthesis delivery.

- Bleeding index and plaque index were evaluated at four sites around each implant-abutment interface at the one-year examination with a periodontal probe (PCPUNC156, Hu-Friedy, Milan, Italy).

An independent dentist evaluated the implant and prosthetic survival and success rates and administered the patient satisfaction and OHIP questionnaires. Complications were assessed and treated by the treating clinician, who was nonblinded. Marginal bone level changes were evaluated by an independent radiologist. An independent blinded dental hygienist who was otherwise not involved in the study performed all of the periodontal measurements.

All data analysis was carried out according to a pre-established analysis plan using software (IBM SPSS Statistics for Macintosh, Version 22.0, IBM, Armonk, N.Y., U.S.). Descriptive analysis was performed using means, standard deviations and a 95% confidence interval. Comparison of the means for marginal bone level changes, patient satisfaction and OHIP scores between the baseline and one-year follow-up examinations was

performed by paired tests. A biostatistician with expertise in dentistry analyzed the data.

Results

A total of 18 Osstem TSIII implants of 8.5 mm ($n = 2$) or 10 mm ($n = 16$) in length and a regular diameter ($n = 9$) or mini diameter ($n = 9$) were placed in nine consecutive edentulous participants (seven female and two male) presenting with Cawood and Howell Class V ($n = 6$) or VI ($n = 3$) mandibular atrophy. The participants were followed up for a minimum of one year (mean: 18.2 months; range: 12–22) after definitive loading. The average age of the patients was 68 (range: 53–77). The main patient and implant characteristics are shown in **Table 1**. No participants dropped out, and no deviation from the original protocol occurred. At the one-year follow-up, no implants or prosthesis had failed, resulting in cumulative implant and prosthetic survival rates of 100%. No biological or technical complications occurred during the follow-up, resulting in cumulative implant and prosthetic success rates of 100%. At the one-year follow-up, the mean marginal bone loss was 0.39 ± 0.15 mm. The OHIP summary scores demonstrated a significant decrease between the pre-treatment scenario and the one-month after prosthesis delivery ($p = 0.0000$) and between the one-month and one-year follow-ups ($p = 0.0005$), after retention system replacement. At the one-year follow-up, the bleeding index was 8.3% and the plaque index was 9.7%. All of the data are summarized in **Table 1**.

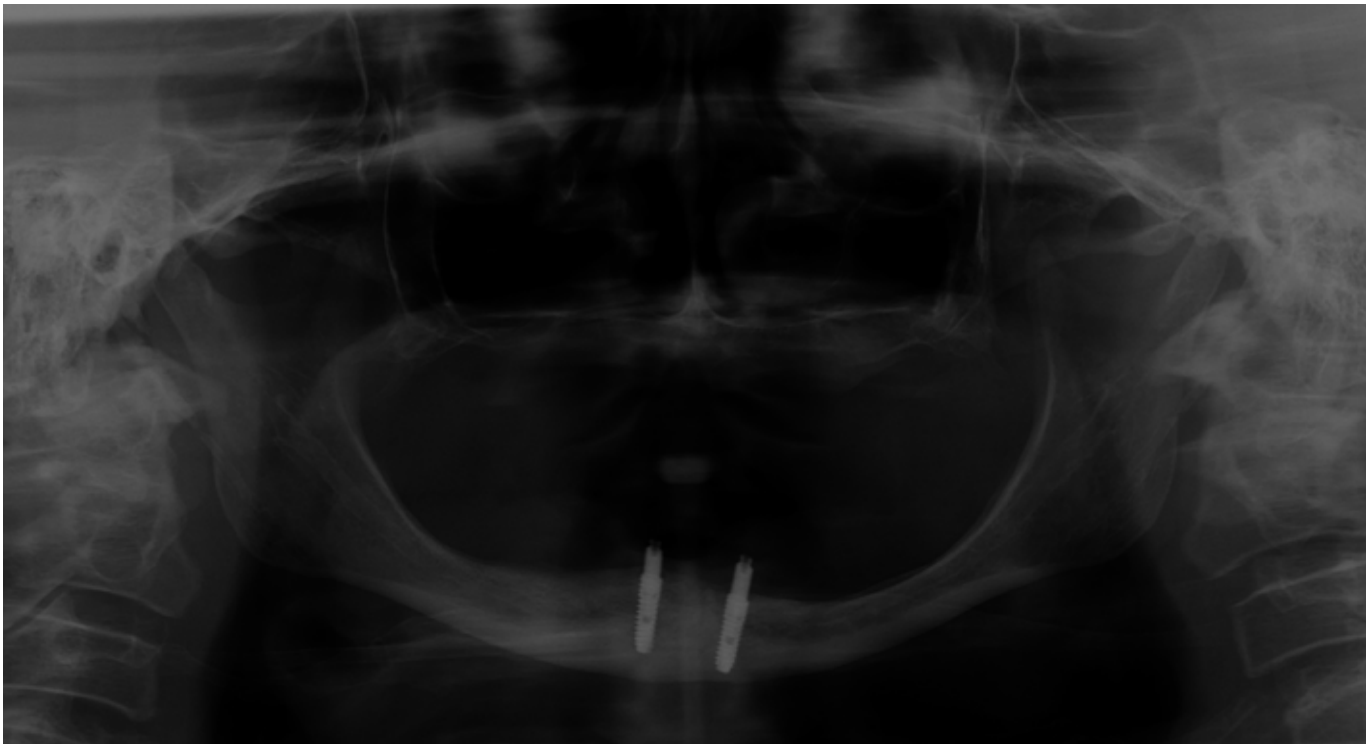


Fig. 8

Fig. 8
Postoperative radiograph.

Discussion

This prospective case series study was designed to evaluate the one-year clinical and radiographic outcomes and patient satisfaction of Cawood and Howell Class V and VI patients treated with a mandibular overdenture supported by two implants using a novel low-profile retention system. Because it was designed as a single-cohort study without sample size calculation, the main limitations were the lack of a control group and a small sample size. Hence, this investigation should be considered as a proof of concept for future multicenter randomized clinical trials with control group comparison.

The results of the present one-year preliminary prospective case series study reported implant and prosthetic survival and success rates of 100% and greater patient satisfaction, indicating that patients with extremely atrophic mandibles (Cawood and Howell Class V and VI) may be rehabilitated using fixed-removable solution.

Owing to increased life expectancy, the treatment of elderly patients is advancing in medicine. With the alveolar bone resorbed and the vertical dimension of the mandible reduced, an altered relationship to the maxilla; poor, variable bone for implant restoration; and loss of cheek and lip support result. According to the literature, implant-retained mandibular overden-

tures can be an effective treatment option for patients who have persistent problems with conventional dentures.⁴ Various attachment systems have been successfully utilized to connect these overdentures to the implants including bar, ball, magnetic and resilient telescopic attachments.¹⁶ A relatively recent attachment that has become increasingly popular is the OT Equator low-profile direct implant overdenture attachment (**Fig. 7**). It is a resilient and self-aligning attachment system with stable retention. Owing to its low profile, it can be used with limited interarch distance. In addition, in the present study, the low-profile OT Equator attachments were used to rehabilitate severely atrophic patients, reducing the risk of denture base fracture over time. In addition, OT Equator attachments allow for angle compensation of up to 30°, which may be helpful in severely atrophic patients with different severities of mandibular atrophy and lingual concavities that may compromise the ability to place axial implants without bone reconstruction. Furthermore, the new Smart Box allows passive insertion under extreme conditions, also up to 50° divergence (**Fig. 8**).

The findings of this study support the established evidence base for improvement in edentulous patients' satisfaction with their prostheses when two implants are used to retain their

complete mandibular dentures, even in severely atrophic patients. In the present study, extra-soft or soft retentive caps were used during the first month after loading in order to allow for easy management by patients. The stronger retentive caps were used to improve the balance between mucosal support and implant retention, also increasing patient satisfaction.

A mandibular overdenture supported by two implants is a well-proven treatment option for severely atrophic patients when a conventional removable denture is not sufficient to ensure function and esthetics. In this historic time, in which the average age of patients has increased, it is important to have a minimally invasive, safe and predictable treatment option that can greatly improve quality of life of patients.

Conclusion

Within the limitations of this study, a mandibular overdenture supported by two implants can be considered an effective and predictable option for successful treatment of patients presenting with Cawood and Howell Class V or VI mandibular atrophy. After a short period of accommodation, it is recommended to replace the conventional retention caps with stronger ones to improve overdenture stability and thus patient satisfaction.

Competing interests

All authors declare no conflicts of interest.

References

- Albrektsson T, Blomberg S, Brånemark A, Carlsson GE. Edentulousness—an oral handicap. Patient reactions to treatment with jawbone-anchored prostheses. → J Oral Rehabil. 1987 Nov;14(6):503–11.
- Allen PF. Association between diet, social resources and oral health related quality of life in edentulous patients. → J Oral Rehabil. 2005 Sep;32(9):623–8.
- Ellis JS, Burawi G, Walls A, Thomason JM. Patient satisfaction with two designs of implant supported removable overdentures; ball attachment and magnets. → Clin Oral Implants Res. 2009 Nov;20(11):1293–8.
- Harris D, Höfer S, O'Boyle CA, Sheridan S, Marley J, Benington IC, Clifford T, Houston F, O'Connell B. A comparison of implant-retained mandibular overdentures and conventional dentures on quality of life in edentulous patients: a randomized, prospective, within-subject controlled clinical trial. → Clin Oral Implants Res. 2013 Jan;24(1):96–103.
- Chiapasco M, Abati S, Romeo E, Vogel G. Implant-retained mandibular overdentures with Brånemark System MKII implants: a prospective comparative study between delayed and immediate loading. → Int J Oral Maxillofac Implants. 2001 Jul-Aug;16(4):537–46.
- Romeo E, Chiapasco M, Lanza A, Casentini P, Ghisolfi M, Iorio M, Vogel G. Implant-retained mandibular overdentures with ITI implants. → Clin Oral Implants Res. 2002 Oct;13(5):495–501.
- Turkyilmaz I, Tumer C. Early versus late loading of unsplinted TiUnite surface implants supporting mandibular overdentures: a 2-year report from a prospective study. → J Oral Rehabil. 2007 Oct;34(10):773–80.
- Hyland R, Ellis J, Thomason M, El-Feky A, Moynihan P. A qualitative study on patient perspectives of how conventional and implant-supported dentures affect eating. → J Dent. 2009 Sep;37(9):718–23.
- Thomason JM, Kelly SA, Bendkowski A, Ellis JS. Two implant retained overdentures—a re-view of the literature supporting the McGill and York consensus statements. → J Dent. 2012 Jan;40(1):22–34.
- Pozzi A, Tallarico M, Moy PK. Four-implant overdenture fully supported by a CAD-CAM titanium bar: a single-cohort prospective 1-year preliminary study. → J Prosthet Dent. 2016 Oct;116(4):516–23.
- Weinländer M, Piehslinger E, Krennmaier G. Removable implant-prosthetic rehabilitation of the edentulous mandible: five-year results of different prosthetic anchorage concepts. → Int J Oral Maxillofac Implants. 2010 May-Jun;25(3):589–97.
- Cawood JI, Howell RA. A classification of the edentulous jaws. → Int J Oral Maxillofac Surg. 1988 Aug;17(4):232–6.
- Elm von E, Altman DG, Egger M, Pocock SJ, Gøtzsche PC, Vandenbroucke JP; STROBE Initiative. Strengthening of Reporting of Observational Studies in Epidemiology (STROBE) statement: guidelines for reporting observational studies. → BMJ. 2007 Oct 20;335(7624):806–8.
- Tallarico M, Vaccarella A, Marzi GC. Clinical and radiological outcomes of 1- versus 2-stage implant placement: 1-year results of a randomised clinical trial. → Eur J Oral Implantol. 2011 Spring;4(1):13–20.
- Tallarico M, Meloni SM. Open-cohort prospective study on early implant failure and physio-logical marginal remodeling expected using sandblasted and acid-etched bone level implants featuring an 11° Morse taper connection within one year after loading. → J Oral Science Rehabilitation. 2017 Mar;3(1):68–79.
- Elsyad MA, Khairallah AS, Shawky AF. Changes in the edentulous maxilla with ball and telescopic attachments of implant-retained mandibular overdentures: a 4-year retrospective study. → Quintessence Int. 2013 Jul;44(7):487–95.